REMUNOM
ISSN 2178-6925

Received: 13/01/2026 - **Accepted:** 06/04/2026
Vol: 13.05
DOI: 10.66104/1epwtw35
Pages: 1-23

EVALUATION OF FEMALE SEX HORMONES ON PERIODONTAL TISSUES OF OBESE RATS SUBJECTED TO EXPERIMENTAL PERIODONTITIS

AVALIAÇÃO DOS HORMÔNIOS SEXUAIS FEMININOS SOBRE OS TECIDOS PERIODONTAIS DE RATAS OBESAS SUBMETIDAS À PERIODONTITE EXPERIMENTAL

EVALUACIÓN DE LAS HORMONAS SEXUALES FEMENINAS EN LOS TEJIDOS PERIODONTALES DE RATAS OBESAS SOMETIDAS A PERIODONTITIS EXPERIMENTAL

Poliana de Fátima Biederman
[1]Cirurgiã-dentista. Mestre em Biociências e Saúde da Universidade Estadual do Oeste do Paraná (UNIOESTE) – Campus Cascavel/PR, Brasil.
E-mail: poliana.biederman@gmail.com

Alana Zenilda Thomaz Sacht
[2]Cirurgiã-dentista. Mestranda em Odontologia pela Universidade Estadual do Oeste do Paraná (UNIOESTE) – Campus Cascavel/PR, Brasil.
E-mail: alanasacht43@icloud.com

Vitoria Bortolon Jassniker
[3]Cirurgiã-dentista. Mestranda em Odontologia pela Universidade Estadual do Oeste do Paraná (UNIOESTE) – Campus Cascavel/PR, Brasil.
E-mail: vitoriabjassniker@gmail.com

Mateus Pacer de Lima
[4]Cirurgião-dentista. Mestrando em Odontologia pela Universidade Estadual do Oeste do Paraná (UNIOESTE) – Campus Cascavel/PR, Brasil.
E-mail: mateuspacer@gmail.com

Carlos Augusto Nassar
[5]Cirurgião–dentista. Doutor em Periodontia. Professor adjunto da disciplina de Periodontia e do Programa de Pós-Graduação em Odontologia da UNIOESTE – Campus Cascavel/PR – Brasil.
E-mail: canassar@yahoo.com

Rose Meira Costa
[6]Bióloga e farmacêutica. Doutora em Ciências - Zoologia. Professora adjunta da disciplina de Biologia Celular e do Programa de Pós-Graduação em Biociências e Saúde da UNIOESTE – Campus Cascavel/PR – Brasil.
E-mail: rosecb@gmail.com

Sara Cristina Sagae
[7]Bióloga. Doutora em Ciências Biológicas. Professora adjunta da disciplina de Fisiologia da UNIOESTE – Campus Cascavel/PR – Brasil.
E-mail: sara.sagae@unioeste.br

REMUNOM
ISSN 2178-6925

Received: 13/01/2026 - **Accepted:** 06/04/2026
Vol: 13.05
DOI: 10.66104/1epwtw35
Pages: 1-23

Patricia Oehlmeyer Nassar
[8]Cirurgiã-dentista. Doutora em Odontologia. Professora adjunta da disciplina de Periodontia e do Programa de Pós-Graduação em Odontologia da UNIOESTE – Campus Cascavel/PR – Brasil.
Email: ponassar@yahoo.com

Abstract

Objective: The aim of this study was to evaluate the effect of hormonal influence on the periodontal tissues of adult rats in the proestrus phase of the estrous cycle, with experimentally induced obesity through a cafeteria diet, associated or not with periodontal disease. Design: For this study, 20 adult cycling female rats in the proestrus phase of the estrous cycle were divided into a control group (CON), a ligature group (LIG), a cafeteria group (CAF), and a cafeteria and ligature group (CAFLIG). At 75 days of age, the animals in the LIG and CAFLIG groups received a ligature around the first right lower molar, which acted as a gingival irritant for 30 days, favoring the accumulation of bacterial plaque and consequent development of periodontal disease. After euthanasia, at 105 days of age, blood was collected from the right brainstem to determine estradiol and progesterone concentrations using specific kits; and the dissection of the right hemi-mandible, which was submitted to histological analysis. The data obtained were analyzed and evaluated using ANOVA and Tukey tests. Results: The results demonstrate a decrease in the concentration of female sex hormones when obesity and periodontal disease were associated; similarly, marked bone resorption and changes in bone tissue morphology were observed in the CAF/LIG group. Conclusion: Based on the results obtained, this study can conclude that the decrease in female sex hormones associated with obesity and periodontal disease negatively interfered with mandibular bone tissue.

Keywords: Obesity; Periodontal disease; Bone tissue.

Resumo

Objetivo: o objetivo do presente estudo foi avaliar o efeito da influência hormonal nos tecidos periodontais de ratas adultas na fase do proestro do ciclo estral, com obesidade induzida experimentalmente, através da dieta de cafeteria, associada ou não a doença periodontal. *Design:* Para a realização deste estudo 20 ratas fêmeas adultas ciclando, na fase do proestro do ciclo estral foram divididas em grupo controle (CON), grupo ligadura (LIG), grupo cafeteria (CAF) e grupo cafeteria e ligadura (CAFLIG). Aos 75 dias de vida, os animais do grupo LIG e CAFLIG receberam uma ligadura ao redor do primeiro molar inferior direito que atuou como irritante gengival por 30 dias, favorecendo o acúmulo de placa bacteriana e consequente desenvolvimento da doença periodontal. Após a eutanásia, aos 105 dias de vida, realizou-se a coleta de sangue do tronco cerebral direito para a determinação das concentrações de estradiol e progesterona utilizando-se *kits* específicos; e a dissecação da hemi- mandíbula direita, que foi submetida à análise histológica. Os dados obtidos foram analisados e avaliados através dos testes ANOVA e Tukey. Resultados: Os resultados demonstram uma diminuição na concentração dos hormônios sexuais femininos quando obesidade e doença periodontal foram associadas; da mesma forma observou-se reabsorção óssea acentuada e mudança na morfologia do tecido ósseo no grupo CAF/LIG. *Conclusão:* Com base nos resultados obtidos o presente estudo pode concluir que a diminuição nos hormônios sexuais femininos associados à obesidade e doença periodontal interferiu negativamente no tecido ósseo mandibular.

Palavras-chave: Obesidade; Doença Periodontal; Tecido ósseo.

REMUNOM
ISSN 2178-6925

Received: 13/01/2026 - **Accepted:** 06/04/2026
Vol: 13.05
DOI: 10.66104/1epwtw35
Pages: 1-23

Resumen

Objetivo: El objetivo de este estudio fue evaluar el efecto de la influencia hormonal sobre los tejidos periodontales de ratas adultas en la fase de proestro del ciclo estral, con obesidad inducida experimentalmente a través de una dieta de cafetería, asociada o no a enfermedad periodontal. Diseño: Para este estudio, 20 ratas hembras adultas en ciclo en la fase de proestro del ciclo estral se dividieron en un grupo control (CON), un grupo de ligadura (LIG), un grupo de cafetería (CAF) y un grupo de cafetería y ligadura (CAFLIG). A los 75 días de edad, los animales de los grupos LIG y CAFLIG recibieron una ligadura alrededor del primer molar inferior derecho, que actuó como irritante gingival durante 30 días, favoreciendo la acumulación de placa bacteriana y el consecuente desarrollo de enfermedad periodontal. Después de la eutanasia, a los 105 días de edad, se recolectó sangre del tronco encefálico derecho para determinar las concentraciones de estradiol y progesterona utilizando kits específicos; y la disección de la hemimandíbula derecha, que se sometió a análisis histológico. Los datos obtenidos se analizaron y evaluaron mediante pruebas ANOVA y de Tukey. Resultados: Los resultados demuestran una disminución en la concentración de hormonas sexuales femeninas cuando se asociaron la obesidad y la enfermedad periodontal; de igual manera, se observó una marcada resorción ósea y cambios en la morfología del tejido óseo en el grupo CAF/LIG. Conclusión: Con base en los resultados obtenidos, este estudio puede concluir que la disminución de las hormonas sexuales femeninas asociada con la obesidad y la enfermedad periodontal interfirió negativamente en el tejido óseo mandibular.

Palabras clave: Obesidad; Enfermedad periodontal; Tejido óseo.

1.Introduction

Considered one of the most significant public health problems worldwide, obesity and overweight represent the leading preventable cause of mortality after tobacco use (HAMDY, 2025) and the fifth leading cause of death globally (WHO, 2012). According to the World Health Organization (WHO), in a publication released in December 2025, it was estimated that, in 2022, approximately 2.5 billion adults (≥18 years) were overweight, corresponding to 43% of the global population. Furthermore, the WHO reports that a body mass index (BMI) above the recommended range was responsible for approximately 3.7 million deaths (WHO, 2026).

Adipose tissue is a metabolically active endocrine organ characterized by cellular heterogeneity (adipocytes, pre-adipocytes, fibroblasts, endothelial, and immune cells), which actively participate in hormonal and immunometabolic processes (LIU; ARIAS et al., 2024; SON et al., 2025). In conditions of excess, its endocrine and inflammatory functions become dysregulated and pathogenic, contributing to metabolic

REMUNOM
ISSN 2178-6925

Received: 13/01/2026 - **Accepted:** 06/04/2026
Vol: 13.05
DOI: 10.66104/1epwtw35
Pages: 1-23

disorders such as insulin resistance, chronic inflammation, and metabolic syndrome (ARIAS et al., 2024; DUAN et al., 2024).

Over the years, obesity has been extensively investigated using experimental animal models to elucidate the mechanisms involved in the development of obesity-related pathologies (KLEINERT et al., 2018). Among the most commonly employed models are those induced by neurological or genetic alterations (BRAY; YORK, 1979), chemical lesions in hypothalamic regions (SUZUKI et al., 1990; SEGAL et al., 1991), and, more recently, diet-induced obesity models based on hypercaloric or high-fat diets (SCLAFANI; SPRINGER, 1976; SPEAKMAN, 2019). High-calorie dietary protocols are designed to mimic human obesity conditions. In this context, the cafeteria diet has emerged as a robust experimental model, promoting weight gain, increased adiposity, and significant metabolic alterations, including insulin resistance (LLADO et al., 1995), elevated circulating leptin levels (WEI et al., 2004), reduced sensitivity to its anorexigenic effects, and the development of arterial hypertension in rodents (COATMELLEC-TAGLIONI et al., 2002; KAGIOS et al., 2025).

Although some evidence suggests that obesity may exert protective effects on bone mass, this notion has been increasingly challenged due to the potential enhancement of catabolic stimuli in bone tissue associated with obesity (CHEN; ARMAMENTO-VILLAREAL, 2023; BIAMONTE et al., 2025). Obesity is characterized by a chronic low-grade inflammatory state, in which adipocytes and immune cells promote the release of pro-inflammatory cytokines and glucocorticoids, favoring osteoclast differentiation and bone resorption while inhibiting osteogenic differentiation (MIGLIACCIO et al., 2007; ZHAO et al., 2008; BIAMONTE et al., 2025).

Similarly, sex hormones play a crucial role in the growth and maintenance of bone mass (BORELLI, 1994; ZHANG et al., 2024). Estrogen deficiency is considered one of the main risk factors for the development of osteoporosis in women, as it represents the primary cause of postmenopausal bone loss (SZEJNFELD, 2003; ZHANG et al., 2024). Following menopause, due to the decline in ovarian estrogen production, most circulating estrogen is derived from the peripheral conversion of androgens via the

REMUNOM
ISSN 2178-6925

Received: 13/01/2026 - **Accepted:** 06/04/2026
Vol: 13.05
DOI: 10.66104/1epwtw35
Pages: 1-23

aromatase enzyme present in adipose tissue (MESEGUER et al., 2002; VENKEN et al., 2008; KURYŁOWICZ, 2023; LEE; DEN, 2025). In obese individuals, adipocytes—responsible for aromatase production—are hypertrophied, leading to increased enzyme activity and estrogen synthesis (ZHAO; REID et al., 2008; LEE; DEN, 2025). Estrogen produced through adipose tissue aromatization represents an important hormonal source, which may partly explain the lower fracture rates observed in obese women (ZHAO; REID et al., 2008; LEE; DEN, 2025).

The hypothesis that ovarian hormones may enhance gingival inflammation and exacerbate the response to local irritants has been supported by several studies. Gingival inflammation appears to be aggravated by fluctuations and/or increased levels of sex hormones, particularly estrogen and progesterone, which modulate immune and inflammatory responses in periodontal tissues (BOYAPATI et al., 2021). Both in vitro and in vivo studies have demonstrated that sex hormones influence and modify the function of immune cells. Additionally, evidence suggests that interactions between estrogen and immune cells may exert non-immune regulatory effects, influencing tissue homeostasis and the host response to periodontal inflammation (CUTOLO et al., 2007).

The similarity between the hormonal profile of female rats and that of women makes rats an excellent experimental model for reproductive studies. Accordingly, much of the current knowledge regarding the regulation of the ovarian cycle in mammals with spontaneous ovulation is derived from studies of the rat estrous cycle (SMITH et al., 1975; ZUCKER, 2023). The rat estrous cycle provides a natural framework for studying variations in plasma concentrations of ovarian and pituitary steroids, as well as their physiological effects on the vaginal epithelium, sexual behavior, and ovulation (SMITH et al., 1975). In this context, the present study aimed to evaluate the effect of hormonal influence on the periodontal tissues of adult rats during the proestrus phase of the estrous cycle, with experimentally induced obesity via a cafeteria diet, associated or not with periodontal disease.

REMUNOM
ISSN 2178-6925

Received: 13/01/2026 - **Accepted:** 06/04/2026
Vol: 13.05
DOI: 10.66104/1epwtw35
Pages: 1-23

2.Methodology

This study was approved by the Animal Use Ethics Committee (CEUA) of UNIOESTE (Protocol No. 05412). Sample size calculation was based on the independent samples t-test and on data from the literature (Duarte et al., 2004), with 90% power and a 1% significance level, resulting in a total sample size of 20 animals.

Animals

Twenty adult cycling Wistar rats in the proestrus phase of the estrous cycle (body weight between 180 and 350 g) were obtained from the central animal facility and housed in the sectorial animal facility of the Physiology and Biophysics Laboratory (CCBS). Animals were kept in individual cages under controlled temperature and a 12-hour light–dark cycle, with food provided ad libitum. The day of birth was considered day 0, and at 21 days postpartum, the litter was weaned, with females housed in groups of 3 to 5 per cage. Body weight (on alternate days) and food intake (daily) were monitored throughout the experimental period. For food intake assessment, the remaining food (leftover from the previous day) was removed and weighed, and then the daily food portion (previously calculated) was provided.

After two days of acclimatization, the reproductive cycle phases of the rats were assessed through vaginal cytology. Samples were collected daily in the morning by vaginal lavage using a plastic pipette containing 10 µL of saline solution (NaCl 0.9%), with the pipette tip inserted shallowly into the vagina. The saline was introduced once or twice, and the vaginal fluid was placed onto a histological slide. The material was not fixed and was observed fresh under a light microscope using 10× and 40× objectives (MARCONDES et al., 2002; HUBSCHER et al., 2005; CORA et al., 2015).

Experimental groups

The animals were divided into four groups:

1. Control Group (CON): rats fed a standard diet and water from weaning to adulthood.

REMUNOM
ISSN 2178-6925

Received: 13/01/2026 - **Accepted:** 06/04/2026
Vol: 13.05
DOI: 10.66104/1epwtw35
Pages: 1-23

2. Ligature Group (LIG): rats fed a standard diet and water from weaning to adulthood, with periodontal disease induced by ligature.
3. Cafeteria Group (CAF): rats fed a cafeteria diet from weaning to adulthood.
4. Cafeteria + Ligature Group (CAFLIG): rats fed a cafeteria diet from weaning to adulthood, with periodontal disease induced by ligature at 75 days.

Cafeteria Diet

From 21 days of age until euthanasia, animals assigned to the cafeteria diet received a modified diet adapted from a previous study (PRADA et al., 2005), consisting of standard chow and additional foods. The modified chow pellet contained 37.5% standard chow, 25% roasted peanuts, 25% chocolate, and 12.5% cornstarch biscuits, comprising 49% carbohydrates, 22% protein, and 24% fat. The ingredients were ground, mixed with water to form pellets, and dried in an oven. The cafeteria diet provided a total of 5.42 kcal/g, whereas the standard diet (control animals) provided 2.95 kcal/g (60% carbohydrates, 22% protein, and 10% fat). Animals in the experimental groups also received non-carbonated soft drinks and water, while control animals received standard chow (Nutrilab™, Colombo, Brazil) and water. Diets were offered daily at the same time, with free access to all components.

Induction of Periodontal Disease

At 75 days of age, animals were anesthetized (xylazine 0.04 mL/100 g and ketamine 0.08 mL/100 g) and positioned on an appropriate surgical table that allowed maintenance of mouth opening, facilitating access to the posterior mandibular teeth. Using a modified forceps and an explorer probe, a No. 40 cotton ligature was placed around the lower right first molar. This ligature acted as a gingival irritant for 30 days, promoting bacterial plaque accumulation and, consequently, the development of periodontal disease (KAUFFMAN, 2022).

REMUNOM
ISSN 2178-6925

Received: 13/01/2026 - **Accepted:** 06/04/2026
Vol: 13.05
DOI: 10.66104/1epwtw35
Pages: 1-23

Blood Sample Collection for LH and Progesterone

At 105 days, animals were euthanized by decapitation, and trunk blood was collected. Blood samples were centrifuged at 3000 rpm, and plasma was separated and stored at −20 °C for determination of LH and progesterone concentrations.

Hormonal assays were performed by radioimmunoassay. Progesterone concentrations were determined using specific kits (Progesterone DSL–3400, Diagnostics Systems Laboratories, Texas, USA), with a minimum detection limit of 0.34 ng/mL. LH radioimmunoassay was performed using a specific kit provided by the National Hormone and Peptide Program (Harbor-UCLA Medical Center, USA). The antibody used was anti-rat LH-S10, and the standard was LH-RP3. The minimum detection limit for LH was 0.04 ng/mL.

Histological Processing

After euthanasia, right hemimandibles were collected and fixed in 10% formalin for 24 hours. Subsequently, specimens were washed in running water for 1 hour and immersed in a formic acid solution prepared with 820 mL of distilled water and 180 mL of 85% formic acid per liter. Samples were maintained in the decalcifying solution for 20 days, with daily monitoring of decalcification and replacement of the solution every 5 days. After this period, specimens were again washed in running water for 1 hour and subjected to dehydration and clearing in an automatic tissue processor for approximately 12 hours (Leica Microsystems® TP1020, Nussloch, Germany). Specimens were then embedded in paraffin (purified paraffin, Vetec Química Fina, Rio de Janeiro, Brazil), sectioned at 7 µm using a semi-automatic microtome (Hestion®, ERM3000, Daintree Scientific, Australia), and mounted on histological slides. Sections were stained with hematoxylin and eosin and Mallory's trichrome.

REMUNOM
ISSN 2178-6925

Received: 13/01/2026 - **Accepted:** 06/04/2026
Vol: 13.05
DOI: 10.66104/1epwtw35
Pages: 1-23

Microscopic Analysis

Microscopic analysis was performed by a trained examiner blinded to the experimental procedures. Histological sections were evaluated under a transmitted light microscope (Leica Microsystems, Switzerland) for morphological analysis of gingival tissue and alveolar process, as well as osteocyte counting in the hemimandibles.

Ethics Committee

The study was approved by the Animal Use Ethics Committee (CEUA/UNIOESTE) and conducted in accordance with the Ethical Principles in Animal Experimentation established by the Brazilian College for Animal Experimentation (COBEA).

Data Analysis

Normality and homogeneity of variance were tested prior to statistical analysis. As data showed normal distribution and homoscedasticity, one-way parametric ANOVA was applied, followed by Tukey's multiple comparisons test. Differences were considered statistically significant at $p < 0.05$ (5%).

---

3. Results

Hormonal Influence on Periodontal Tissues

Statistical analysis demonstrated no significant differences among the experimental groups regarding progesterone levels (Table 1). However, significant differences were observed among groups in relation to luteinizing hormone (LH) concentrations. Compared to the CON and LIG groups, the CAF group showed a statistically significant difference in LH levels. This difference was also observed when comparing the CAFLIG group with both the CON and LIG groups.

REMUNOM
ISSN 2178-6925

Received: 13/01/2026 - **Accepted:** 06/04/2026
Vol: 13.05
DOI: 10.66104/1epwtw35
Pages: 1-23

These findings indicate that animals subjected to the cafeteria diet exhibited lower LH concentrations compared to those receiving a standard diet. Furthermore, when periodontal disease was associated with obesity (CAFLIG group), LH levels were further reduced, suggesting a combined influence of obesity and periodontal disease on the concentration of this hormone.

Table 1. Blood levels of progesterone and LH in rats from the experimental groups.

Group	Progesterone	LH
CONTROL	43,6±32,1 ^{A}	6,9±2,9 ^{A}
LIGATURE	47,3±35,4 ^{A}	6,3±2,4 ^{A}
CAFETERIA	32,8±17,3 ^{A}	2,0±2,8 ^{B}
CAFETERIA + LIGATURE	27,3±12,9 ^{A}	1,2±0,3 ^{B}

Values are expressed as mean ± standard deviation.
Different letters indicate statistically significant differences within the same evaluation parameter ($p < 0.05$).

Morphological Analysis

Animals from the CON, CAF, LIG, and CAF/LIG groups exhibited an alveolar bone crest of moderate thickness, with its height varying according to the experimental group (Figure 1).

Analysis of the alveolar bone crest revealed osteoclastic areas with Howship's lacunae, indicating bone resorption. These areas were more pronounced in the CAF/LIG group (Figure 2). In addition, the presence of incremental lines, organization of some Haversian canals, and aligned osteoblasts positioned adjacent to the bone crest was observed, indicating ongoing bone formation activity in all studied groups (Figure 3).

Furthermore, evaluation of the alveolar bone crest demonstrated distinct bone patterns when comparing the CAF/LIG group to the other groups. The CON group, as well as the CAF and LIG groups, exhibited compact and regular bone, whereas the

REMUNOM
ISSN 2178-6925

Received: 13/01/2026 - **Accepted:** 06/04/2026
Vol: 13.05
DOI: 10.66104/1epwtw35
Pages: 1-23

CAF/LIG group showed a predominance of trabecular (spongy) bone with thin alveolar bone crests (Figure 4).



Figure 1. Photomicrograph of a rat tooth, control group, hematoxylin and eosin staining, sagittal section. The image shows the measurement sites for alveolar bone crest height and the distance from the crest to the cementoenamel junction (dashed line) in the studied groups. Alveolar bone crest (COA) and cementoenamel junction (JCE).

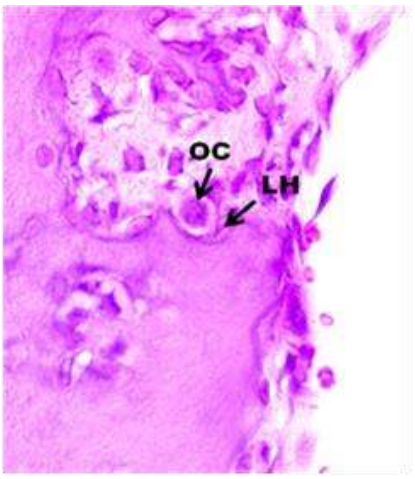

Figure 2. Photomicrograph of a rat tooth, CAFLIG group, hematoxylin and eosin staining, 1000× magnification, sagittal section. The image demonstrates bone resorption observed in all studied groups. Osteoclast occupying a Howship's lacuna (LH), indicating bone resorption by the presence of osteoclasts (OC).

REMUNOM
ISSN 2178-6925

Received: 13/01/2026 - **Accepted:** 06/04/2026
Vol: 13.05
DOI: 10.66104/1epwtw35
Pages: 1-23



Figure 3. Photomicrograph of the alveolar bone crest of a rat tooth, control group, hematoxylin and eosin staining, sagittal section. The image shows evidence of bone formation in all studied groups, including areas of bone formation with the presence of incremental lines (LI) and osteoblasts (OB).

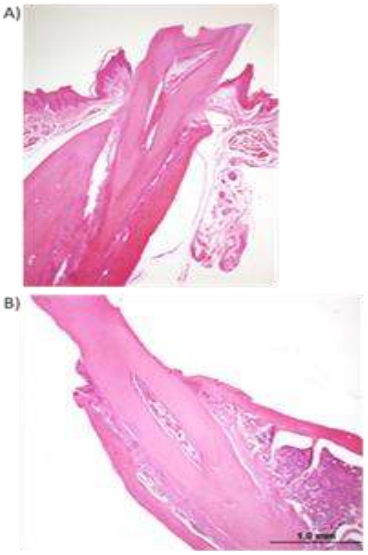

Figure 4. Photomicrograph of a rat tooth, control group, hematoxylin and eosin staining, sagittal section. Representative of the bone patterns observed in the studied groups. It shows the compact bone pattern found in the CON, LIG, and CAF groups (A) and the trabecular (spongy) bone pattern observed in the CAFLIG group (B).

Morphometric Analysis

Microscopic analysis included measurement of the distance from the cementoenamel junction to the alveolar bone crest in order to assess the presence or absence of bone loss. In addition, counts of osteoblasts, osteocytes, and osteoclasts were performed to determine bone resorption or bone formation in the studied groups.

Analysis of the distance from the alveolar bone crest to the cementoenamel junction (Table 2) demonstrated that, although this distance—and therefore bone resorption—was greater in the LIG group compared to the CAF group, both groups presented significantly higher mean values than the control group, suggesting that both obesity and periodontal disease lead to bone loss. Furthermore, when comparing the CAF/LIG group with the other experimental groups, it was observed that it exhibited

REMUNOM
ISSN 2178-6925

Received: 13/01/2026 - **Accepted:** 06/04/2026
Vol: 13.05
DOI: 10.66104/1epwtw35
Pages: 1-23

the highest mean distance, indicating that bone loss associated with both obesity and periodontal disease is exacerbated when these two conditions are combined.

Table 2. Mean values of the distance from the cementoenamel junction to the alveolar bone crest in rats from the experimental groups (µm).

Group	Mean (µm)
CONTROL	579.2±43.0 ^{A}
LIGATURE	662.4±31.8 ^{B}
CAFETERIA	1033.4±51.3 ^{C}
CAFETERIA + LIGATURE	1276.4±78.7 ^{D}

Values are expressed as mean ± standard deviation. Different letters indicate statistically significant differences within the same evaluation parameter ($p < 0.05$).

The results obtained from cell counting (Table 3) demonstrated a decrease in the number of osteoblasts and osteocytes in the LIG, CAF, and CAF/LIG groups when compared to the CTL group. In contrast, the number of osteoclasts was significantly higher in the experimental groups compared to the CTL group, initially suggesting that both the induction of periodontal disease and obesity result in bone loss.

REMUNOM
ISSN 2178-6925

Received: 13/01/2026 - **Accepted:** 06/04/2026
Vol: 13.05
DOI: 10.66104/1epwtw35
Pages: 1-23

Table 3. Mean (± SD) values of osteoblasts, osteoclasts, and osteocytes in the experimental groups.

Group	Osteoblasts	Osteocytes	Osteoclasts
CONTROL	76.7±12.3 [A]	361.2±30.9[A]	1.0±0.4 [A]
LIGATURE	62,3±6.7 [B]	316.6±16.6 [B]	2.3±0,4 [B]
CAFETERIA	61.7±4.7 [B]	300.8±18.3 [B]	2.1±0.7 [B]
CAFETERIA + LIGATURE	54.0±4.0 [C]	250.4±15.4 [C]	3.1±0,7 [C]

When comparing the experimental groups with each other, no significant differences were observed between the LIG and CAF groups regarding the number of evaluated cells. However, both groups showed significant differences when compared to the CAF/LIG group, which exhibited a lower number of osteoblasts and osteocytes and a higher number of osteoclasts relative to the other groups. These findings further suggest that bone loss is exacerbated when obesity and periodontal disease are associated.

4. Discussion

Although estrogen measurements have not yet been obtained, this preliminary analysis of LH levels may suggest that estrogen concentrations could show statistically significant differences among the same groups, given that this hormone induces LH secretion during the follicular phase (HERBISON, 2008; KAUFFMAN, 2022).
Sex steroids exert multiple functions in bone tissue, including stimulation of osteoblastic activity, inhibition of calcium mobilization from the body, and reduction in osteoclast formation and activity (SØRENSEN et al., 2006; HSU et al., 2024), in addition

REMUNOM
ISSN 2178-6925

Received: 13/01/2026 - **Accepted:** 06/04/2026
Vol: 13.05
DOI: 10.66104/1epwtw35
Pages: 1-23

to promoting rapid bone calcification, leading to a reduction or cessation of proliferative activity in the epiphyseal plate (SCHICHT et al., 2014; TSUCHIDA et al., 2025). Therefore, the reduction in plasma LH concentrations observed in the initial results of this study—and consequently a possible reduction in estradiol—may negatively influence the periodontal tissues of rats subjected to experimental periodontitis, despite the absence of changes in progesterone levels.

In a study conducted with 372 postmenopausal women, Ageel et al. (2025) evaluated the association between hormone replacement therapy (HRT) and periodontal health. Clinical parameters such as probing depth and clinical attachment level were assessed, and the results indicated that HRT was associated with a 3.2-fold lower likelihood of periodontitis compared to the control group (AGEEL et al., 2025). Furthermore, hormonal fluctuations occurring during menopause, puberty, pregnancy, and menstruation, as well as those resulting from hormone supplementation, may lead to increased gingival inflammation and reduced alveolar bone density (PALANISAMY, 2025).

The results of the present study demonstrated a reduction in LH concentration and, consequently, a possible decrease in estrogen levels in the CAF and CAF/LIG groups (KLEINERT et al., 2018; KAUFFMAN, 2022). In addition, both groups exhibited alveolar bone loss compared to the CTL group. The LIG group, although not showing significant differences in hormone concentrations compared to CTL, also presented bone resorption, suggesting that bacterial plaque accumulation is a determining factor in bone loss. Classical studies and recent evidence indicate that, although estrogen deficiency potentiates systemic and local bone loss, hormone replacement therapy shows limited efficacy in the presence of active bacterial inflammation (DUARTE et al., 2004; ROSSETTI et al., 2022), since plaque accumulation negatively modulates the host response regardless of hormonal status (RITTER et al., 2025).

Evidence from experimental models of ovarian hormone deficiency has shown that reduced estrogen levels impair alveolar bone density (KURYŁOWICZ, 2023). This condition alters the host immune-inflammatory response and establishes hormonal deficiency as an important risk factor for the progression and severity of bone

REMUNOM
ISSN 2178-6925

Received: 13/01/2026 - **Accepted:** 06/04/2026
Vol: 13.05
DOI: 10.66104/1epwtw35
Pages: 1-23

resorption in the presence of periodontal disease (MIGLIACCIO et al., 2007; LEE; DEN, 2025). However, based on findings from previous studies, ovarian hormone deficiency alone could not be considered a risk factor for periodontal disease, as no significant differences were observed between ovariectomized and non-ovariectomized animals.

Considering that obese individuals often present higher bone mineral density (BMD) compared to eutrophic individuals, obesity has been suggested as a protective factor against fractures and osteoporosis (REID, 2008; BOYAPATI et al., 2021). The large amount of adipose tissue in obese individuals may enhance the biotransformation of androgens into estrogens, increasing circulating levels of sex steroids and positively influencing bone mass (MESEGUER et al., 2002; KURYŁOWICZ, 2023). Studies have demonstrated higher concentrations of sex hormones in obese women compared to eutrophic individuals (CUTOLO et al., 2007).

Although the biological mechanisms through which obesity affects the periodontium are not yet fully elucidated, several studies have demonstrated an association between periodontal disease and obesity across different populations (BRAY; YORK, 1979; HAMDY, 2025). The biological plausibility of this association likely involves immuno-inflammatory pathways, as adipose tissue secretes pro-inflammatory cytokines in proportion to body mass (WHO, 2012; SON et al., 2025). In obese individuals, elevated levels of inflammatory mediators such as TNF-α, IL-1, and IL-6 may promote a hyperinflammatory state, increasing the risk of development or progression of periodontal disease (BRAY; YORK, 1979). Additionally, the production and release of neutrophils, as well as T and B lymphocytes, may be altered in obesity (ZUCKER, 2023). Periodontal tissue repair capacity may also be impaired due to increased glucose and lipid levels, which can contribute to an exaggerated inflammatory response and inhibition of growth factor production by macrophages (COATMELLEC-TAGLIONI et al., 2002; ZUCKER, 2023).

According to Zhao et al. (2022), obesity is associated with increased bone mass, favoring bone formation and maintenance of mineral density due to mechanical loading and hormonal contributions from adipose tissue. However, the fundamental

REMUNOM
ISSN 2178-6925

Received: 13/01/2026 - **Accepted:** 06/04/2026
Vol: 13.05
DOI: 10.66104/1epwtw35
Pages: 1-23

mechanisms underlying this effect remain unclear and are often attributed to increased mechanical load on the skeleton (BRAY; YORK, 1979). In contrast, the present study demonstrated bone loss, based on the CEJ–ABC distance, in animals subjected to the cafeteria diet, with further exacerbation when associated with periodontal disease. A possible explanation for this discrepancy is that, in this study, female sex hormones—particularly estrogen, which plays a protective role in bone mass (SCLAFANI; SPRINGER, 1976; MESEGUER et al., 2002; MIGLIACCIO et al., 2007; VENKEN et al., 2008; KURYŁOWICZ, 2023) — were reduced in the experimental groups, which also exhibited greater bone loss.

A systematic review investigating the association between obesity and periodontal disease conducted by Moura-Grec et al. (2023) evaluated 31 studies, of which 25 reported a positive association and only 6 found no association, indicating a significant relationship between obesity and periodontal disease (PRADA et al., 2005). The findings of the present study also demonstrated an association between these conditions, with greater alveolar bone resorption observed when obesity and periodontal disease were combined, suggesting a negative influence of obesity on bone mass (CUTOLO et al., 2007).

Conversely, Dias et al. (2023), in a study involving 100 non-smoking, systemically healthy patients who had not received periodontal treatment in the previous 6 months or used antibiotics/anti-inflammatory drugs in the last 3 months, found no association between obesity and periodontal disease (ZUCKER, 2023). Some authors suggest that obesity-related alterations in pro-inflammatory and immune responses may increase susceptibility to periodontal disease; however, the underlying cellular and molecular mechanisms remain unclear, requiring further investigation (HERBISON, 2008; WHO, 2012; WHO, 2026).

Supporting these findings, a study conducted in Japan reported a high prevalence of periodontal disease among young obese adults, particularly among obese women (SCLAFANI; SPRINGER, 1976).

Regarding cellular quantification, osteocytes are the most abundant cells in bone tissue under normal conditions (BORELLI, 1994), and their quantity may reflect bone maturity (CUTOLO et al., 2007). In the present study, the number of osteocytes

REMUNOM
ISSN 2178-6925

Received: 13/01/2026 - **Accepted:** 06/04/2026
Vol: 13.05
DOI: 10.66104/1epwtw35
Pages: 1-23

and osteoblasts was reduced in the CAF and LIG groups compared to the control group, with a more pronounced reduction in the CAF/LIG group. In contrast, osteoclast numbers were increased, particularly in the CAF/LIG group, suggesting enhanced bone resorption, as increased osteoclast numbers are directly associated with bone resorption (MIGLIACCIO et al., 2007; ZHAO et al., 2008). Moreover, a positive relationship was observed between the number of active osteoclasts on the bone surface and the CEJ–ABC distance, reinforcing the occurrence of bone loss and demonstrating that obesity associated with periodontal disease affects bone tissue (LEE; DEN, 2025).

Regarding morphological analysis, measurement of the distance between the alveolar bone crest and the cementoenamel junction (ABC–CEJ) allows evaluation of changes resulting from periodontal disease, eruptive tooth movement, or systemic factors such as diabetes and smoking (SUZUKI et al., 1990), and can therefore be considered a reliable parameter for assessing alveolar bone loss. In this study, an increase in the CEJ–ABC distance was observed in the treated groups, with the greatest distance found in the CAF/LIG group, indicating alveolar bone loss.

Under normal physiological conditions, bone formation and resorption are balanced, such that osteoclastic activity is followed by osteoblastic activity (ZHAO et al., 2008). Although areas of both bone formation and resorption were observed in all groups, this study demonstrated increased osteoclastic activity in the treated groups compared to the control group, particularly in the CAF/LIG group, further confirming the occurrence of alveolar bone loss (BRAY; YORK, 1979; CUTOLO et al., 2007).

The CAF/LIG group exhibited a distinct bone pattern compared to the other groups, characterized by a predominance of trabecular (spongy) bone and a thinner alveolar bone crest, indicating that the association between obesity and periodontal disease promotes morphological alterations in bone tissue.

5. Conclusion

Based on the results obtained, this experimental study demonstrated that the

REMUNOM
ISSN 2178-6925

Received: 13/01/2026 - **Accepted:** 06/04/2026
Vol: 13.05
DOI: 10.66104/1epwtw35
Pages: 1-23

reduction in the concentration of the evaluated female sex hormones (progesterone and LH), associated with cafeteria diet-induced obesity and periodontal disease, negatively affected alveolar bone mass. These conditions led to changes in bone cell quantification (osteoclasts, osteoblasts, and osteocytes) and in mandibular bone morphology. However, further studies are needed to better understand the potential consequences and mechanisms underlying the association of the pathologies investigated, as well as how this interaction may influence bone mass.

References

AGEEL, R.; ABAALKHAIL, B.; NATTO, Z. S. Effect of hormone replacement therapy on periodontal health in post-menopausal women in Jeddah, Saudi Arabia. **BMC Women's Health**, v. 25, n. 1, p. 383, 2025.

ARIAS, C. et al. Enhancing adipose tissue functionality in obesity: senotherapeutics, autophagy and cellular senescence as a target. **Biological Research**, v. 57, n. 1, ago. 2024.

BIAMONTE, E. et al. Bone Health in Metabolic Syndrome-Is It a Neglected Aspect of Dysmetabolic-Related Diseases? **Journal of Clinical Medicine**, v. 14, n. 16, p. 5785, ago. 2025.

BORELLI, A. Envelhecimento ósseo: osteoporose. In: CARVALHO FILHO, E. T.; PAPALÉO NETTO, M. **Geriatria: fundamentos, clínica e terapêutica**. São Paulo: Atheneu, cap. 22, p. 297-308, 1994.

BOYAPATI, R. et al. Influence of female sex hormones in different stages of women on periodontium. **Journal of Mid-life Health**, v. 12, n. 4, p. 263, 2021.

BRAY, G. A.; YORK, D. A. Hypothalamic and genetic obesity in experimental animals: an autonomic and endocrine hypothesis. **Physiology Reviews**, v. 59, n. 3, p. 719-809, 1979.

CORA, M.C.: KOOISTRA L.: TRAVLOS, G. Vaginal Cytology of the Laboratory Rat and Mouse: Review and Criteria for the Staging of the Estrous Cycle Using Stained Vaginal Smears. **Toxicol Pathol,** v.43, p. 776-793, 2015.

REMUNOM
ISSN 2178-6925

Received: 13/01/2026 - **Accepted:** 06/04/2026
Vol: 13.05
DOI: 10.66104/1epwtw35
Pages: 1-23

CHEN, R.; ARMAMENTO-VILLAREAL, R. Obesity and Skeletal Fragility. **The Journal of Clinical Endocrinology & Metabolism**, jul. 2023.

COATMELLEC-TAGLIONI, G. et al. Gender difference in diet-induced obesity hypertension: implication of renal alpha2-adrenergic receptors. **American Journal of Hypertension**, v. 15, p. 143-149, 2002.

CUTOLO, M. et al. Estrogens, the immune response and autoimmunity. **Clinical and Experimental Rheumatology**, v. 13, n. 2, p. 217-226, 2007.

DIAS, P. et al. Relationship between obesity and periodontal disease: a cross-sectional study. **Journal of Periodontology**, v. 84, n. 3, 2023.

DUAN, F. et al. Deciphering Endocrine Function of Adipose Tissue and Its Significant Influences in Obesity-Related Diseases Caused by Its Dysfunction. **Differentiation**, v. 141, p. 100832, dez. 2024.

DUARTE, P. M. et al. Effect of an estrogen-deficient state and its therapy on bone loss resulting from an experimental periodontitis in rats. **Journal of Periodontal Research**, v. 39, p. 107-110, 2004.

HAMDY, O. **Obesity: Background, Pathophysiology, Etiology**. Medscape, 2025. Disponível em: http://emedicine.medscape.com/article/123702-overview. Acesso em: 3 mar. 2026.

HERBISON, A. E. Estrogen positive feedback to gonadotropin-releasing hormone (GnRH) neurons in the rodent: the case for the rostral periventricular area of the third ventricle (RP3V). **Brain Research Reviews**, v. 57, n. 2, p. 277-287, 2008.

HSU, S.-H.; CHEN, L.-R.; CHEN, K.-H. Primary Osteoporosis Induced by Androgen and Estrogen Deficiency: The Molecular and Cellular Perspective on Pathophysiological Mechanisms and Treatments. **International Journal of Molecular Sciences**, v. 25, n. 22, p. 12139, 2024.

HUBSCHER, C. H.: BROOKS, D.L.; JOHNSON, J.R. A quantitative method for assessing stages of the rat estrous cycle. **Biotech Histochem**, v.80, p. 79-87, 2005.

KAGIOS, C. et al. Cafeteria diet and caloric restriction affect metabolic but not behavioral characteristics in male Wistar rats. **Physiology & Behavior**, v. 288, p. 114731, jan. 2025.

REMUNOM
ISSN 2178-6925

Received: 13/01/2026 - **Accepted:** 06/04/2026
Vol: 13.05
DOI: 10.66104/1epwtw35
Pages: 1-23

KAUFFMAN, A. S. Neuroendocrine mechanisms underlying estrogen positive feedback and the LH surge. **Frontiers in Neuroscience**, v. 16, p. 953252, 2022.

KLEINERT, M. et al. Animal models of obesity and diabetes mellitus. **Nature Reviews Endocrinology**, v. 14, n. 3, p. 140–162, mar. 2018.

KURYŁOWICZ, A. Estrogens in Adipose Tissue Physiology and Obesity-Related Dysfunction. **Biomedicines**, v. 11, n. 3, p. 690, fev. 2023.

LEE, A. A.; DEN, L. J. Metabolic impact of endogenously produced estrogens by adipose tissue in females and males across the lifespan. **Frontiers in Endocrinology**, v. 16, out. 2025.

LIU, Y. et al. The secretory function of adipose tissues in metabolic regulation. **Life Metabolism**, jan. 2024.

LLADO, I. et al. Protein and amino acid intake in cafeteria fed obese rats. **Physiology & Behavior**, v. 58, p. 513-519, 1995.

MARCONDES, F.K.; BIANCHI F.J.; TANNO, A.P. Determination of the estrous cycle phases of rats: some helpful considerations. **Braz J Biol,** v.62, p. 609-14, 2002.

MESEGUER, A.; PUCHE, C.; CABERO, A. Sex steroid biosynthesis in white adipose tissue. **Hormone Metabolic Research**, v. 34, p. 731-736, 2002.

MIGLIACCIO, S. et al. Glucocorticoid-induced osteoporosis: an osteoblastic disease. **Aging Clinical Experimental Research**, v. 19, p. 5-10, 2007.

MOURA-GREC, P. G. et al. Obesity and periodontitis: systematic review and meta-analysis. **CAERN**, 2023.

PALANISAMY, S. The impact of estrogen on periodontal tissue integrity and inflammation: a mini review. **Frontiers in Dental Medicine**, v. 6, p. 1455755, 2025.

PRADA, P. O. et al. Western diet modulates insulin signaling, c-Jun n-Terminal kinase activity, and insulin receptor substrate-1ser307 phosphorylation in a tissue-specific fashion. **Endocrinology**, v. 146, p. 1576-1587, 2005.

REID, I. R. Relationship between fat and bone. **Osteoporosis International**, v. 9, p. 595-606, 2008.

REMUNOM
ISSN 2178-6925

Received: 13/01/2026 - **Accepted:** 06/04/2026
Vol: 13.05
DOI: 10.66104/1epwtw35
Pages: 1-23

RITTER, C. et al. Soluble epoxide hydrolase inhibition preserves alveolar bone in experimental periodontitis with estrogen deficiency. **Frontiers in Immunology**, v. 16, p. 1708504, 2025.

ROSSETTI, B. R. et al. Effects of estrogen deficiency on the progression of apical periodontitis: a systematic review of preclinical studies. **Archives of Oral Biology**, v. 142, p. 105496, 2022.

SCHICHT, M. et al. Articular cartilage chondrocytes express aromatase and use enzymes involved in estrogen metabolism. **Arthritis Research & Therapy**, v. 16, n. 2, p. R93, 2014.

SCLAFANI, A.; SPRINGER, D. Dietary in obesity in adult rats: similarities to hypothalamic and human syndromes. **Physiology & Behavior**, v. 17, p. 461-471, 1976.

SEGAL, M. M.; BELL, J.; ABRAMS, G. M. Hypothalamic or central obesity associated with an early rise in plasma insulin concentration. **Archives of Neurology**, v. 48, p. 429-431, 1991.

SMITH, M. S.; FREEMAN, M. E.; NEILL, J. D. The control of progesterone secretion during the estrous cycle and early pseudopregnancy in the rat. **Endocrinology**, v. 96, p. 219-226, 1975.

SON, Y. et al. Immunometabolic crosstalk in adipose tissue remodeling: mechanisms and therapeutic perspectives. **Journal of Obesity & Metabolic Syndrome**, v. 34, n. 4, p. 344–361, out. 2025.

SØRENSEN, M. G. et al. Estrogen directly attenuates human osteoclastogenesis, but has no effect on resorption by mature osteoclasts. **DNA Cell Biology**, v. 25, n. 8, p. 475-483, ago. 2006.

SPEAKMAN, J. R. Use of high-fat diets to study rodent obesity as a model of human obesity. **International Journal of Obesity**, v. 43, n. 8, p. 1491–1492, abr. 2019.

SUZUKI, N. et al. Hypothalamic obesity due to hydrocephalus caused by aqueductal stenosis. **Journal of Neurology Neurosurgery and Psychiatry**, v. 53, p. 1102-1103, 1990.

REMUNOM
ISSN 2178-6925

Received: 13/01/2026 - **Accepted:** 06/04/2026
Vol: 13.05
DOI: 10.66104/1epwtw35
Pages: 1-23

SZEJNFELD, V. L. Alterações ósseas: fisiopatologia, diagnóstico e tratamento. In: FERNANDES, C. E. **Menopausa: diagnóstico e tratamento**. 1. ed. São Paulo: Seguimento, 2003.

TSUCHIDA, J. et al. Effects of estrogen and mechanical loading on cultured cells derived from mandibular condylar cartilage. **Scientific Reports**, v. 15, n. 1, p. 23470, 2025.

VENKEN, K. et al. Sex hormones, their receptors and bone health. **Osteoporosis International**, v. 19, p. 1517–1525, 2008.

WEI, S. et al. Obesity and diabetes in transgenic mice expressing pro SAAS. **Journal of Endocrinology**, v. 180, p. 357-368, 2004.

WORLD HEALTH ORGANIZATION (WHO). **Obesity and overweight, May 2012**. Seção Media Centre. Disponível em: http://www.who.int/mediacentre/factsheets/fs311/en/index.html. Acesso em: 29 jun. 2013.

WORLD HEALTH ORGANIZATION (WHO). **Obesity and Overweight**. 2025/2026. Disponível em: https://www.who.int/news-room/fact-sheets/detail/obesity-and-overweight. Acesso em: fev. 2026.

ZHANG, Y.-Y. et al. Insights and implications of sexual dimorphism in osteoporosis. **Bone Research**, v. 12, n. 1, p. 1–30, fev. 2024.

ZHAO, L. J. et al. Correlation of obesity and osteoporosis: effect of fat mass on the determination of osteoporosis. **Journal of Bone and Mineral Research**, v. 23, p. 17-29, 2008.

ZHAO, L. J. et al. Obesity, Bone Loss, and Periodontitis: The Interlink. Biomolecules,. **Journal of Bone and Mineral Research**, v.12, n.7, p.865, 2022.

ZUCKER, I. The mixed legacy of the rat estrous cycle. **Biology of Sex Differences**, v. 14, n. 1, set. 2023.