REMUNOM
ISSN 2178-6925

Received: 24/06/2026 - **Accepted:** 28/07/2026
Vol: 13.17
DOI: 10.66104/ty162544
Pages: 1-13

ABORDAGEM MULTIDISCIPLINAR NO MANEJO DE REABSORÇÃO RADICULAR CERVICAL EXTERNA COM REPARO BIOCERÂMICO E ENXERTIA DE TECIDO CONJUNTIVO - RELATO DE CASO

MULTIDISCIPLINARY APPROACH TO THE MANAGEMENT OF EXTERNAL CERVICAL ROOT RESORPTION WITH BIOCERAMIC REPAIR AND CONNECTIVE TISSUE GRAFTING – CASE REPORT

ENFOQUE MULTIDISCIPLINARIO PARA EL TRATAMIENTO DE LA REABSORCIÓN RADICULAR CERVICAL EXTERNA MEDIANTE REPARACIÓN BIOCERÁMICA E INJERTO DE TEJIDO CONECTIVO - INFORME DE CASO

Vitor Rodrigues da Silva
Doutorando em Clínica Odontológica com Ênfase em Dentística pelo Programa de Pós-graduação da Universidade de Campinas, Brasil
E-mail: v207042@dac.unicamp.br

Thais Flügel Mathias Paschoal
Doutoranda em Clínica Odontológica com Ênfase em Periodontia pelo Programa de Pós-graduação da Universidade de Campinas, Brasil

Cintia Moreira Gonçalves
Doutoranda em Materiais Odontológicos pelo Programa de Pós-graduação da Universidade de Campinas, Brasil

Leticia Sandoli Arroteia
Doutoranda em Clínica Odontológica com Ênfase em Periodontia pelo Programa de Pós-graduação da Universidade de Campinas, Brasil

Leticia Tank Oliveira
Doutoranda em Clínica Odontológica com Ênfase em Endodontia pelo Programa de Pós-graduação da Universidade de Campinas, Brasil

Débora Costa Ruiz
Pós-doutoranda na Universidade Federal do Espírito Santo, UFES, Brasil

Rafael Pino Vitti
Professor Associado em Clínica Odontológica com ênfase em Dentística na Universidade de Campinas, Brasil

Enílson Antônio Sallum
Professor Titular em Clínica Odontológica com ênfase em Periodontia na Universidade de Campinas, Brasil

REMUNOM
ISSN 2178-6925

Received: 24/06/2026 - **Accepted:** 28/07/2026
Vol: 13.17
DOI: 10.66104/ty162544
Pages: 1-13

Flavio Henrique Baggio Aguiar
Professor Titular em Clínica Odontológica com ênfase em Dentística na Universidade de Campinas, Brasil

Resumo

Este relato de caso descreve o manejo de uma reabsorção radicular cervical externa (RRCE) em uma paciente do sexo feminino, 32 anos, cirurgiã-dentista, sem alterações sistêmicas. A paciente apresentava histórico de tratamento endodôntico no dente 11 na adolescência, seguido de restauração protética com faceta em dissilicato de lítio (EMAX). Clinicamente, observou-se mobilidade leve, extrusão, sangramento e supuração recorrente, com profundidade de sondagem de 10 mm e recessão gengival de 1 mm. Testes de sensibilidade pulpar foram negativos, e a percussão e palpação foram positivas. A tomografia computadorizada de feixe cônico (TCFC) confirmou o diagnóstico de RRCE, classificando a lesão como Grau 3 de Heithersay e 3Dp de Patel. A intervenção cirúrgica incluiu desbridamento do tecido reabsortivo, reparo com Biodentine® e enxerto de tecido conjuntivo subepitelial (15x4 mm) do palato. O acompanhamento de 24 meses demonstrou estabilidade clínica, redução da profundidade de sondagem para 4 mm, ausência de sintomatologia e alta satisfação da paciente. A integração de diagnóstico tridimensional, biomateriais e técnicas periodontais plásticas é crucial para a preservação de dentes anteriores com lesões extensas.
Palavras-chave: Relato de Caso, Cirurgia periodontal, Cimentos de silicato de cálcio, Reabsorção cervical externa, Reabsorção radicular.

Abstract

This case report describes the management of external cervical root resorption (ECRR) in a 32-year-old female patient, a dentist, with no systemic alterations. The patient had a history of endodontic treatment on tooth #11 during adolescence, followed by a lithium disilicate (EMAX) veneer restoration. Clinically, slight mobility, extrusion, bleeding, and recurrent suppuration were observed, with a probing depth of 10 mm and 1 mm gingival recession. Pulp sensitivity tests were negative, and percussion and palpation were positive. Cone-beam computed tomography (CBCT) confirmed the diagnosis of ECRR, classifying the lesion as Heithersay Grade 3 and Patel 3Dp. Surgical intervention included debridement of the resorptive tissue, repair with Biodentine®, and a subepithelial connective tissue graft (15x4 mm) from the palate. The 24-month follow-up demonstrated clinical stability, reduction in probing depth to 4 mm, absence of symptoms, and high patient satisfaction. The integration of three-dimensional diagnosis, biomaterials, and plastic periodontal techniques is crucial for the preservation of anterior teeth with extensive lesions.
Keywords: Case report, Periodontal surgery, Calcium silicate cements, External cervical resorption, Root resorption.

Resumen

Este informe de caso describe el manejo de la reabsorción radicular cervical externa (RRCE) en una dentista de 32 años sin alteraciones sistémicas. La paciente tenía antecedentes de tratamiento endodóntico en el diente 11 durante la adolescencia, seguido de restauración protésica con una carilla de disilicato de litio (EMAX). Clínicamente, se observó movilidad leve, extrusión, sangrado y supuración recurrente, con una profundidad de sondaje de 10 mm y recesión gingival de 1 mm. Las pruebas de sensibilidad pulpar fueron negativas, y la percusión y palpación fueron positivas. La tomografía computarizada de haz cónico (TCBC) confirmó el diagnóstico de RRCE, clasificando la lesión como grado 3 de Heithersay y 3Dp de Patel. La intervención quirúrgica incluyó desbridamiento del tejido reabsorbido, reparación con Biodentine® y un injerto de tejido conectivo

REMUNOM
ISSN 2178-6925

Received: 24/06/2026 - **Accepted:** 28/07/2026
Vol: 13.17
DOI: 10.66104/ty162544
Pages: 1-13

subepitelial (15x4 mm) del paladar. El seguimiento a los 24 meses demostró estabilidad clínica, una reducción de la profundidad de sondaje a 4 mm, ausencia de síntomas y alta satisfacción del paciente. La integración del diagnóstico tridimensional, los biomateriales y las técnicas de plastia periodontal es crucial para la preservación de los dientes anteriores con lesiones extensas.
Palabras clave: Caso clínico, Cirugía periodontal, Cementos de silicato de calcio, Reabsorción cervical externa, Reabsorción radicular.

1. Introduction

External cervical root resorption (ECRR) is an invasive and destructive pathological condition that originates on the root surface, apical to the epithelial attachment. Its progression is often asymptomatic until advanced stages, where pulpal involvement or severe periodontal compromise may occur. The etiology of ECRR is multifactorial, associated with factors such as dental trauma, orthodontic treatment, internal bleaching, and previous surgical procedures (Heithersay, 1999). Early diagnosis is crucial, as lesion progression can lead to tooth loss if not adequately treated (Patel et al., 2018).

The advent of cone-beam computed tomography (CBCT) revolutionized the diagnosis of ECRR, allowing three-dimensional visualization of the lesion's extent, its relationship with the root canal, and the precise location of the entry point. The classification by Patel et al. (2018), based on CBCT, complements the classic Heithersay classification (1999), providing subsidies for a more predictable therapeutic plan. Treatment aims at eliminating the resorptive tissue and restoring the root defect. Calcium silicate-based materials, such as Biodentine®, have stood out for their excellent biocompatibility, bioactivity, and mechanical properties similar to dentin (Maia et al., 2015). However, in extensive lesions with bone and tissue loss, isolated root repair surgery may result in aesthetic sequelae. In these cases, the association of plastic periodontal surgery techniques, such as the subepithelial connective tissue graft, is fundamental to restore tissue volume and smile harmony (Zucchelli et al., 2016). This report describes the multidisciplinary management of extensive ECRR in a maxillary central incisor, with a two-year follow-up.

REMUNOM
ISSN 2178-6925

Received: 24/06/2026 - **Accepted:** 28/07/2026
Vol: 13.17
DOI: 10.66104/ty162544
Pages: 1-13

2. Case Report

A 32-year-old female patient, a dentist, sought specialized care reporting recurrent bleeding and purulent discharge in the region of tooth #11 for several years. In the anamnesis, the patient denied altered systemic conditions or a history of childhood accidents. She reported having undergone endodontic treatment on tooth #11 during adolescence due to a periapical lesion. After endodontics, the tooth was restored with an EMAX veneer for aesthetic correction. The dental history revealed a thick periodontal phenotype.

Upon clinical examination, tooth #11 presented grade I mobility and slight extrusion. Palpation and percussion responses were positive. Pulp sensitivity tests (cold and heat) were negative, confirming the condition of an endodontically treated and pulpally inert tooth. Periodontal probing revealed a depth of 10 mm on the buccal/mesial aspect, with bleeding and suppuration upon touch. The clinical attachment level (CAL) was 11 mm in the buccal region. A gingival recession of 1 mm was also noted in the zenith area of teeth #11 and #12.

Figure 1: Initial clinical aspect (a) and (b) showing 10 mm periodontal probing and localized gingival recession.

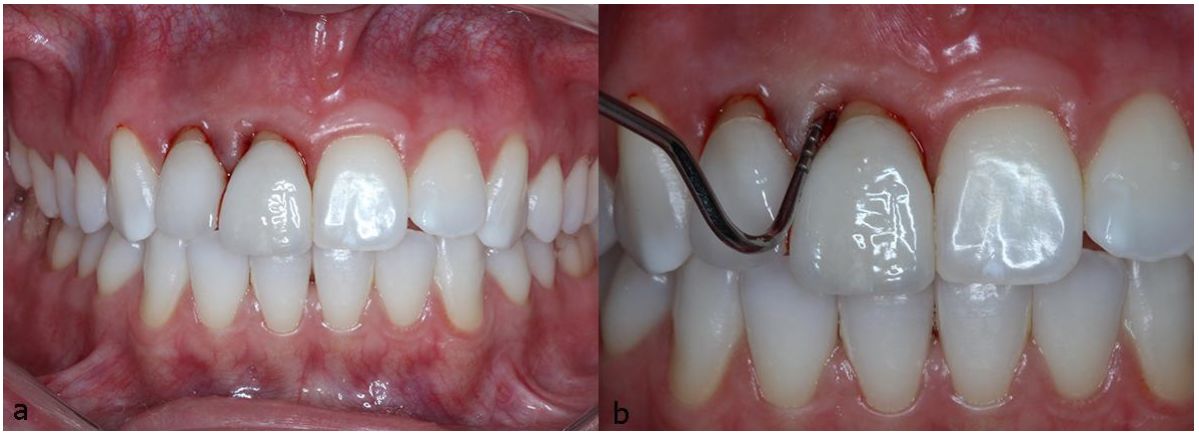

Figure 1 demonstrates the severity of periodontal involvement, suggesting a deep communication with the root defect. To confirm the diagnostic hypothesis, cone-beam computed tomography (CBCT) was requested. Tomographic images revealed an invasive cervical defect compatible with external cervical root resorption, classified as Heithersay Grade 3 (dentin and cementum involvement with extension to the middle third of the root) and Patel 3Dp (deep extension with

REMUNOM
ISSN 2178-6925

Received: 24/06/2026 - **Accepted:** 28/07/2026
Vol: 13.17
DOI: 10.66104/ty162544
Pages: 1-13

partial circumferential involvement). The pulpal diagnosis was pulpal necrosis (endodontically treated tooth) and the periapical diagnosis was chronic apical periodontitis in resolution, without active lesion.

Figure 2: Cone-beam computed tomography images showing the three-dimensional extent of the resorption (axial, coronal, and sagittal views).

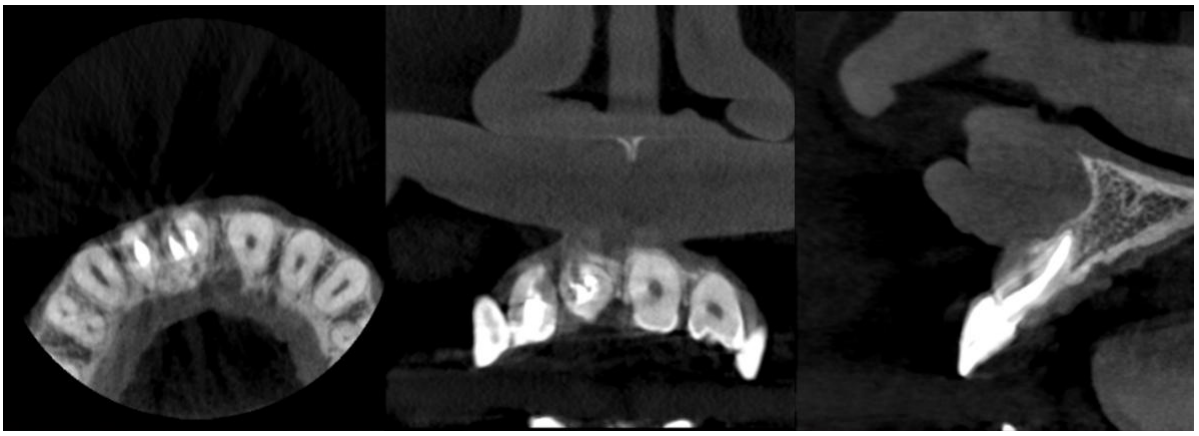

2.1 Surgical and Repair Protocol

Planning consisted of surgical access for debridement and root repair. Preoperative medication protocol included Amoxicillin 1g (single dose 1h before). The procedure was performed under local anesthesia with 2% Lidocaine and 1:100,000 epinephrine. Extra and intraoral antisepsis was performed with 0.12% Chlorhexidine solution.

Magnification (3.5x loupes) was used to ensure debridement precision. The flap design was an envelope type, with intrasulcular incisions extending from tooth #13 to #21, aiming for maximum papilla preservation. After elevation of the mucoperiosteal flap, the bone and root defect was exposed (Figure 3).

Figure 3: Surgical exposure of the external cervical root defect after flap elevation.

REMUNOM
ISSN 2178-6925

Received: 24/06/2026 - **Accepted:** 28/07/2026
Vol: 13.17
DOI: 10.66104/ty162544
Pages: 1-13



Removal of the resorptive tissue was performed with periodontal curettes (Gracey 1/2 and 7/8) and spherical tungsten carbide burs at low speed under constant irrigation with saline solution. The criterion for complete debridement was the visualization of healthy dentin and the absence of granulation tissue or hemorrhagic foci within the cavity, in addition to inspection under magnification. Local bleeding control was achieved with compression with gauze soaked in saline.

For repair, Biodentine® bioceramic cement (Septodont, Saint-Maur-des-Fossés, France) was used. The material was rigorously manipulated according to the manufacturer's instructions: one powder capsule to 5 drops of liquid, taken to the amalgamator for the necessary time. The initial setting time observed was approximately 12 minutes. The material was placed into the cavity with resin spatulas, filling the defect up to 0.5 mm below the remaining bone crest, extending to the gingival level in the final portion of the resorption, with adequate thickness for sealing (Figure 4).

REMUNOM
ISSN 2178-6925

Received: 24/06/2026 - **Accepted:** 28/07/2026
Vol: 13.17
DOI: 10.66104/ty162544
Pages: 1-13

Figure 4: Root repair with Biodentine®.

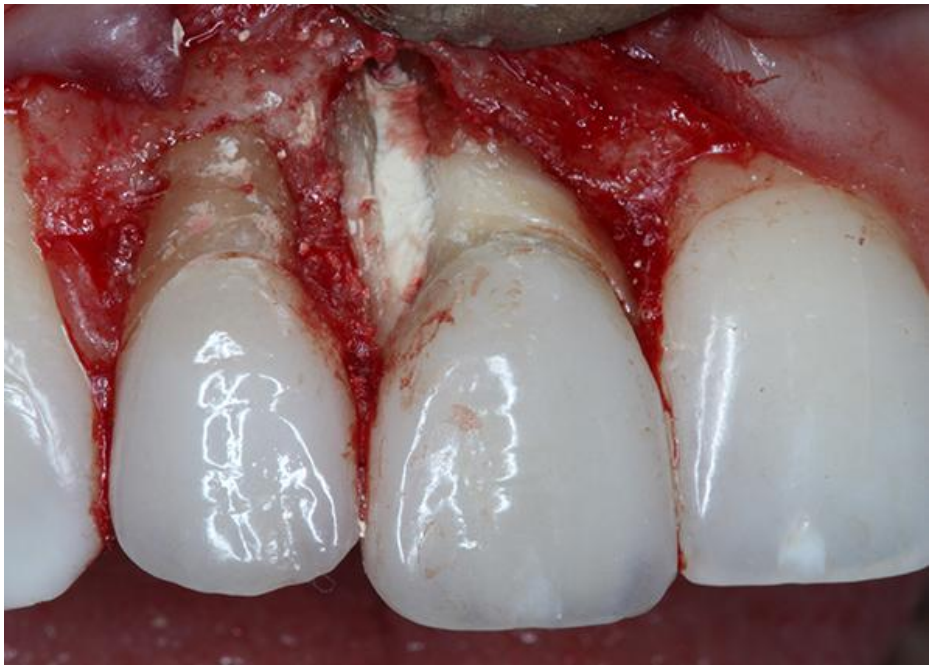

To prevent "wash-out" of Biodentine during the initial setting phase and optimize aesthetics, the external cervical portion was conditioned with the Beatifil X adhesive system (Shofu) and sealed with Beatifil Flow resin (Shofu). This choice was based on its bioactive capacity (Giomer technology) and optical properties that prevent excessive opacity of the bioceramic material under the gingival tissue. Finishing and polishing were performed with rubber points and felt discs.

2.2 Connective Tissue Graft and Closure

To compensate for the volumetric bone defect and improve the gingival phenotype, a subepithelial connective tissue graft was performed. The donor area was the palate, in the premolar region. The double incision technique was used to obtain a graft with approximate dimensions of 15 mm in length, 4 mm in width, and 1.5 mm in thickness.

The donor area was sutured with 4-0 silk sutures and covered with bioactive flowable resin for protection. The graft was positioned over the recipient bed (tooth #11) and stabilized through a combination of flowable resin at the contact points and suspensory sutures with 6-0 monofilament thread (Figure 5).

Figure 4: Subepithelial connective tissue graft harvested from the palatal region and prepared for grafting.

REMUNOM
ISSN 2178-6925

Received: 24/06/2026 - **Accepted:** 28/07/2026
Vol: 13.17
DOI: 10.66104/ty162544
Pages: 1-13



Figure 5: Positioning and stabilization of the subepithelial connective tissue graft.



The main flap was repositioned more coronally than the original position to compensate for the previous gingival recession and ensure full coverage of the graft. Sutures were performed with 6-0 monofilament thread, using a simple interrupted and suspensory suture technique, ensuring papilla preservation. At the end of the procedure, the flap was repositioned more coronally due to pre-existing gingival retraction.

REMUNOM
ISSN 2178-6925

Received: 24/06/2026 - **Accepted:** 28/07/2026
Vol: 13.17
DOI: 10.66104/ty162544
Pages: 1-13

Figure 6: Immediate postoperative appearance with the flap repositioned and sutured, covering the connective tissue graft.



2.3 Postoperative and Follow-up

Postoperative prescription consisted of Nimesulide 100 mg (every 12h for 3 days) and Dipyrone 500 mg (every 6h in case of pain). Hygiene guidelines included suspending brushing in the surgical area for the first 14 days, replaced by delicate cleaning with soft cotton swabs immersed in 0.12% Chlorhexidine solution (Periogard) after the second day. Rinsing with Periogard twice a day, 30 minutes after brushing other areas, was recommended, avoiding vigorous rinses for the first 3 days. Diet was restricted to cold and soft foods for the first 48 hours, progressing to warmer and less aggressive foods after the third day.

Sutures were removed after 14 days, without complications. Patient adherence to treatment was excellent, facilitated by her professional background. Periodic controls were performed at 6 and 28 months, as the patient moved to another country.

Figure 7: Clinical aspect at 6-month follow-up.

REMUNOM
ISSN 2178-6925

Received: 24/06/2026 - **Accepted:** 28/07/2026
Vol: 13.17
DOI: 10.66104/ty162544
Pages: 1-13



Figure 8: Clinical aspect at 28-month follow-up (photo taken with a mobile phone).



At 6 months, probing depth reduced from 10 mm to 4 mm, with absence of bleeding on probing and brushing, no signs of pain or adverse effects. The pulpal condition remained inert. At 28 months, results remained stable, with good aesthetic integration and satisfy periodontal health, resulting in high patient satisfaction. No complications were observed in any of the controls.

REMUNOM
ISSN 2178-6925

Received: 24/06/2026 - **Accepted:** 28/07/2026
Vol: 13.17
DOI: 10.66104/ty162544
Pages: 1-13

3. Discussion

The differential diagnosis of ECRR includes internal resorption and cervical caries. In the present case, the history of previous endodontic treatment could suggest a failure in internal sealing, but CBCT was decisive in identifying the external origin of the lesion and its invasive nature (Patel et al., 2018). The classification by Patel et al. (2018) and Heithersay (1999) allowed understanding that, despite the depth, the lesion did not involve the entire root circumference, which favored the decision for tooth preservation instead of extraction and implant. The absence of control periapical radiographs limits the evaluation of internal bone and root repair, but the clinical findings are encouraging.

Therapeutic alternatives range from monitoring (in incipient cases) to exploratory surgery. The criterion for surgical intervention in this case was the presence of suppuration and pathological probing depth, indicating an active and infected lesion. The need for additional endodontic treatment was ruled out, as the canal was already obturated and the lesion was of external origin, although the history suggests that resorption may have been a contributing factor to the initial chromatic failure in adolescence.

Biodentine® was selected for overcoming limitations of other materials, such as the prolonged setting time of MTA and the risk of staining. However, its opacity can be a challenge in aesthetic areas. The strategy of covering the cervical portion with bioactive flowable resin (Shofu) not only improved the optical result but also protected the cement from early salivary dissolution (Shofu Dental, 2022).

The specific contribution of the connective tissue graft was fundamental. In addition to providing volume to mask the bone defect, the graft created a thick biological barrier that facilitated the coronal repositioning of the flap, simultaneously treating the pre-existing gingival recession (Zucchelli et al., 2016). The risk of ECRR recurrence exists, but hermetic sealing with bioactive material and re-established periodontal health minimizes this possibility. The current prognosis is considered favorable, given the 24-month stability.

This case, although an individual report, integrates a series of cases that our research group is developing on root resorptions. The systematic documentation of

REMUNOM
ISSN 2178-6925

Received: 24/06/2026 - **Accepted:** 28/07/2026
Vol: 13.17
DOI: 10.66104/ty162544
Pages: 1-13

these cases aims to deepen the understanding of etiological factors, treatment options, and long-term results, contributing to the literature and improving clinical guidelines for the management of ECRR. Further studies with larger sample sizes and longer follow-up periods are needed to validate these findings and establish more robust evidence-based protocols. The multidisciplinary approach, combining advanced diagnostic imaging, innovative biomaterials, and refined periodontal plastic surgery techniques, represents a significant advance in preserving teeth affected by extensive ECRR, offering predictable and aesthetically pleasing outcomes for patients.

4. Conclusion

The multidisciplinary management of external cervical root resorption (ECRR) involving advanced diagnostic imaging (CBCT), bioceramic repair with Biodentine®, and subepithelial connective tissue grafting proved to be an effective and predictable approach for the preservation of tooth #11 in this case. The 24-month follow-up demonstrated clinical stability, significant reduction in probing depth, absence of symptoms, and high patient satisfaction. This integrated approach highlights the importance of a comprehensive treatment plan to achieve favorable long-term aesthetic and functional outcomes in complex cases of ECRR.

REMUNOM
ISSN 2178-6925

Received: 24/06/2026 - **Accepted:** 28/07/2026
Vol: 13.17
DOI: 10.66104/ty162544
Pages: 1-13

5. Referências

[1] Heithersay, G. S. (1999). Clinical, radiologic, and histopathologic features of invasive cervical root resorption. Quintessence International, 30(1), 27-37. doi.org/10.1111/j.1601-1546.2004.00060.x

[2] Patel, S., Kanagasingam, S., & Pitt Ford, T. R. (2018). External cervical resorption: a three-dimensional classification. International Endodontic Journal, 51(2), 206-214. doi.org/10.1111/iej.12824

[3] Maia, L. C., de Souza, L. B., de Castro, A. M., & da Silva, R. A. (2015). Biodentine: a review of its properties and clinical applications. Journal of Clinical Pediatric Dentistry, 39(4), 289-294. doi.org/10.17796/1053-4628-39.4.289

[4] Zucchelli, G., Mounssif, I., Mazzotti, C., & Stefanini, M. (2016). The connective tissue graft for the treatment of gingival recessions. Periodontology 2000, 71(1), 129-148. doi.org/10.1111/prd.12128

[5] Manente, R., da Silva Mira, P. C., & Milori Corona, S. A. (2026). Bioactive materials with S-PRG filler in paediatric dentistry: a scoping review. European Archives of Paediatric Dentistry, 27, 275–292. doi.org/10.1007/s40368-025-01077-8