REMUNOM
ISSN 2178-6925

Received: 20/01/2026 - **Accepted:** 07/02/2026
Vol: 02.1
DOI: 10.61164/40077e20
Pages: 1-14

CONSERVATIVE APPROACH TO THE MANAGEMENT OF EXTENSIVE ODONTOGENIC KERATOCYST IN THE MANDIBLE WITH RISK OF PATHOLOGICAL FRACTURE

ABORDAGEM CONSERVADORA NO MANEJO DO QUERATOCISTO ODONTOGÊNICO EXTENSO EM MANDÍBULA COM RISCO DE FRATURA PATOLÓGICA

ENFOQUE CONSERVADOR EN EL TRATAMIENTO DE UN QUISTE ODONTOGÉNICO EXTENSO EN LA MANDÍBULA CON RIESGO DE FRACTURA PATOLÓGICA

Vinícius Franzão Ganzaroli
Master's Degree in Oral and Maxillofacial Surgery, Araçatuba School of Dentistry (FOA-UNESP), Brazil
E-mail: vinicius.ganzaroli@unesp.br

Laura Vidoto Paludetto
Master's Degree in Oral and Maxillofacial Surgery, Araçatuba School of Dentistry (FOA-UNESP), Brazil
E-mail: laura.paludetto@unesp.br

Ana Carolina Zucon Bacelar Marcolino
Master's Degree in Oral and Maxillofacial Surgery, Araçatuba School of Dentistry (FOA-UNESP), Brazil
E-mail: ana.bacelar@unesp.br

Rodrigo Isaías Lopes Pereira
Graduate in Dentisty, Araçatuba School of Dentistry (FOA-UNESP), Brazil
E-mail: rodrigo.l.pereira@unesp.br

Estêvão Lopes Pereira
Graduate in Dentistry, Araçatuba School of Dentistry (FOA-UNESP), Brazil
E-mail: estevão.pereira@unesp.br

Gestter Willian Lattari Tessarin
Doutor of General and Applied Biology, Botucatu institute of Biosciences (IBB-UNESP), Brazil
E-mail: gestter.tessarin@unesp.br

Luan Felipe Toro
Doctor of General and Applied Biology, Botucatu Institute of Biosciences (IBB-UNESP), Brazil
E-mail: luan.toro@unesp.br

REMUNOM
ISSN 2178-6925

Received: 20/01/2026 - **Accepted:** 07/02/2026
Vol: 02.1
DOI: 10.61164/40077e20
Pages: 1-14

Luciana Estevam Simonato
Doctor of Biomedical Engineering, Brazil University (UB), Brazil
E-mail: luciana.simionato@ub.edu.br

Luis Felipe Pupim dos Santos
Doctor of Public Health, Araçatuba School of Dentistry (FOA-UNESP), Brazil
E-mail: luis.santos@ub.edu.br

Daniela Ponzoni
Doctor of Dentistry, Araçatuba School of Dentistry (FOA-UNESP), Brazil
E-mail: daniela.ponzoni@unesp.br

Edilson Ervolino
Doctor of Science, Institute of Biomedical Sciences (ICB-USP), Brazil
E-mail: e.ervolino@unesp.br

Abstract

The present clinical case report aims to describe the conservative surgical management of an extensive odontogenic keratocyst (OK) in the posterior mandibular region, associated with an impacted tooth and near the mandibular canal. A 21-year-old female patient presented with pain and paresthesia in the left mandibular area. Panoramic radiography and cone-beam computed tomography (CBCT) revealed a well-defined, multilocular radiolucent lesion involving the impacted tooth 38 and overlapping the mandibular canal. Initial treatment consisted of an incisional biopsy and cyst decompression, aiming to reduce lesion volume and minimize neurosensory risk. Clinical and radiographic follow-up demonstrated progressive reduction of the cystic cavity and thickening of the cortical bone, while histopathological examination confirmed the diagnosis of odontogenic keratocyst. The patient progressed without pain and paresthesia, maintaining adequate hygiene and good adaptation to the decompression device. The two-stage approach proved effective for initial lesion control and for safely planning definitive treatment, reinforcing that in large lesions located near the inferior alveolar nerve, decompression followed by definitive therapy represents a conservative, predictable, and safe strategy.
Keywords: Odontogenic Cysts; Radiography, Panoramic; Cone-Beam Computed Tomography; Case Reports.

Resumo

O presente relato de caso clínico tem como objetivo descrever o tratamento cirúrgico conservador de um queratocisto odontogênico (QO) extenso na região posterior da mandíbula, associado a um dente impactado e próximo ao canal mandibular. Uma paciente de 21 anos apresentou dor e parestesia na região mandibular esquerda. A radiografia panorâmica e a tomografia computadorizada de feixe cônico (TCFC) revelaram uma lesão radiolúcida multilocular bem definida, envolvendo o dente 38 impactado e sobrepondo-se ao canal mandibular. O tratamento inicial consistiu em uma biópsia incisional e descompressão do cisto, com o objetivo de reduzir o volume da lesão e minimizar o risco neurossensorial. O acompanhamento clínico e radiográfico demonstrou redução progressiva da cavidade cística e espessamento do osso cortical, enquanto o exame histopatológico confirmou o diagnóstico de queratocisto odontogênico. A paciente evoluiu sem dor e parestesia, mantendo higiene adequada e boa adaptação ao dispositivo de descompressão. A abordagem em duas etapas mostrou-se eficaz para o controle inicial da lesão e para o planejamento seguro do tratamento definitivo, reforçando que, em lesões grandes localizadas próximas ao nervo alveolar inferior, a descompressão seguida de terapia definitiva representa uma estratégia conservadora, previsível e segura.

REMUNOM
ISSN 2178-6925

Received: 20/01/2026 - **Accepted:** 07/02/2026
Vol: 02.1
DOI: 10.61164/40077e20
Pages: 1-14

Palavras-chave: Cistos Odontogênicos; Radiografia Panorâmica; Tomografia Computadorizada de Feixe Cônico; Relatos de Casos.

Resumen

El presente informe de caso clínico tiene como objetivo describir el tratamiento quirúrgico conservador de un queratoquiste odontogénico (QO) extenso en la región mandibular posterior, asociado a un diente impactado y muy próximo al canal mandibular. Una paciente de 21 años acudió con dolor y parestesia en la zona mandibular izquierda. La radiografía panorámica y la tomografía computada de haz cónico (TCHC) revelaron una lesión radiotransparente multilocular bien definida que afectaba al diente impactado 38 y se superponía al canal mandibular. El tratamiento inicial consistió en una biopsia incisional y una descompresión del quiste, con el objetivo de reducir el volumen de la lesión y minimizar el riesgo neurosensorial. El seguimiento clínico y radiográfico demostró una reducción progresiva de la cavidad quística y un engrosamiento del hueso cortical, mientras que el examen histopatológico confirmó el diagnóstico de quiste queratocístico odontogénico. La paciente evolucionó sin dolor y parestesia, manteniendo una higiene adecuada y una buena adaptación al dispositivo de descompresión. El enfoque en dos etapas demostró ser eficaz para el control inicial de la lesión y para planificar de forma segura el tratamiento definitivo, lo que refuerza que, en lesiones grandes situadas cerca del nervio alveolar inferior, la descompresión seguida de una terapia definitiva representa una estrategia conservadora, predecible y segura.
Palabras clave: Quistes Odontogénicos; Radiografía Panorámica; Tomografía Computarizada de Haz Cónico; Informes de Casos.

REMUNOM
ISSN 2178-6925

Received: 20/01/2026 - **Accepted:** 07/02/2026
Vol: 02.1
DOI: 10.61164/40077e20
Pages: 1-14

1. Introduction

Odontogenic keratocyst (OK) is currently recognized as a benign intraosseous cystic lesion of development, according to the 5th edition (2022) of the WHO classification for head and neck tumors and cysts. Historically, its designation has fluctuated due to its clinically aggressive behavior and tendency to recur, but the contemporary classification emphasizes anatomopathological criteria and a risk-based approach (Soluk-Tekkesin; Wright, 2022). From an etiopathogenic point of view, OK is considered to be derived from remnants of the dental lamina and structures related to odontogenic development, which helps explain its predilection for the jaws and some of its growth patterns (Soluk- Tekkesin; Wright, 2022).

Accounting for about 10–11% of jaw cysts, it is relatively uncommon when compared to other entities and has a predilection for the posterior region and mandibular ramus. It most often affects young adults, with a slight predominance in males (Borghesi *et al.,* 2018; de Freitas Gonçalves *et al.,* 2024; Mohamed *et al.,* 2023). When symptomatic or voluminous, it can cause tooth displacement, root resorption, and occasionally paresthesia (Borghesi *et al.,* 2018; Gupta *et al.,* 2020; Mohamed *et al.,* 2023). From an imaging perspective, it usually presents as a uni- or multilocular radiolucency with well-defined and often cortical contours; it is not uncommon for it to be associated with unerupted teeth. Cone beam computed tomography (CBCT) scans are useful for determining the extent, relationship with the mandibular canal and maxillary sinus floor, and for planning the surgical approach (Borghesi *et al.,* 2018; Gupta *et al.,* 2020).

Treatment varies according to size, location, involvement of teeth/noble structures, and patient profile. Options include enucleation, decompression/marsupialization followed by enucleation in extensive lesions or those close to risk structures, and the use of adjuvants to reduce recurrence (de Freitas Gonçalves *et al.,* 2024; Dioguardi *et al.,* 2024; Jacobs *et al.,* 2024; Esonu *et al.,* 2023). Given these characteristics, this case report aims to report a case of OK, clarifying the histopathological, clinical, and radiographic findings and the defined treatment strategy.

REMUNOM
ISSN 2178-6925

Received: 20/01/2026 - **Accepted:** 07/02/2026
Vol: 02.1
DOI: 10.61164/40077e20
Pages: 1-14

2. Metodologia

This study consists of a clinical case report, using a qualitative and descriptive approach, developed with the aim of documenting and discussing the clinical, radiographic, and histopathological characteristics of odontogenic keratocyst (OK), correlating them with relevant evidence from the literature.

The collection of clinical information, imaging exams, and histopathological data was performed during the patient's dental care, following the usual diagnostic and therapeutic flow.

All procedures complied with current ethical standards. The patient signed the Free and Informed Consent Form (FICF) provided by the Araçatuba School of Dentistry – FOA/UNESP, authorizing the diagnosis and treatment, as well as the use of images and clinical information for scientific purposes and publication in specialized journals.

3. Case Report

A 21-year-old female patient attended the Oral and Maxillofacial Surgery and Traumatology Clinic at the Araçatuba School of Dentistry – FOA/UNESP, reporting pain for 10 days and paresthesia in the left mandibular region. For the objective assessment of the degree of paresthesia, the Sensory Recovery Scale (Medical Research Council – MRC) was used, which objectively classifies the patient's paresthesia and nerve recovery into levels from S0 to S4. The patient was located at level S2.

During the anamnesis, the patient denied systemic comorbidities, allergies, continuous medication use, and addictions. A detailed intraoral and extraoral clinical examination revealed no noteworthy changes. Due to the reported symptoms, a panoramic radiograph was requested (Figure 1A), which showed an extensive intraosseous lesion in the posterior region of the left mandible, presenting a radiolucent, well-defined, multilocular image associated with the impacted tooth 38, overlapping the mandibular canal. In order to investigate the radiographic finding more precisely and plan for surgical intervention, a CBCT was requested (Figures 1B, 1C, and 1D). When analyzing the axial (Figure 1C) and coronal (Figure 1D) sections, it was observed that the lesion had not fenestrated

REMUNOM
ISSN 2178-6925

Received: 20/01/2026 - **Accepted:** 07/02/2026
Vol: 02.1
DOI: 10.61164/40077e20
Pages: 1-14

the cortical bones, but had expanded through the trabecular bone tissue, causing a risk of pathological fracture. In the sagittal plane (Figure 1B), the impacted tooth 38 was located near the base of the mandible and in close contact with the mandibular canal and the bone lesion, justifying the probable cause of the paresthesia reported by the patient.

A diagnosis of OK was made, next, a treatment plan was drawn up for the patient, who agreed to undergo the procedure. All stages of treatment, from preoperative to postoperative care following the patient's recurrence, are described in our flowchart (Figure 2). Initially, a conservative surgical approach was decided upon, including an incisional biopsy to confirm the diagnosis and cystic decompression. Initially, intraoral and extraoral asepsis was performed, anesthesia was administered by blocking the inferior alveolar, lingual, and buccal nerves, and supplemented with terminal infiltrative anesthesia in the mandibular vestibule, using a 2% mepivacaine hydrochloride solution with 1:100,000 adrenaline. Subsequently, a low monoangular incision was made distal to tooth 37 (Figures 1E and 1F), the mucoperiosteal flap was displaced, and the underlying bone tissue was exposed (Figure 1G). With the aid of a low-speed 702 drill, the bone tissue was perforated and the cystic cavity was opened (Figure 1H), allowing aspiration of the cystic contents (Figure 1I), which had a whitish color, indicating a high keratin content. Next, an osteotomy was performed with a low-speed No. 10 carbide drill (Figure 1J), allowing better access to the cystic cavity (Figure 1K) and enabling the collection of material for shipment to the FOA pathology laboratory. An adapted, sterile latex device with an internal diameter of 3 mm, an external diameter of 5.5 mm, and a depth of 3 mm was introduced into the cystic cavity and secured with simple stitches using 5-0 nylon thread (Figure 1L). At the end of the procedure, antibiotic therapy (amoxicillin 500mg) was prescribed every 8 hours for 7 days, ibuprofen 600mg every 8 hours for 3 days, and analgesic (dipyrone 500mg) every 6 hours if pain was present. The patient received instructions on how to clean the cystic decompression device, which should be irrigated with 15 ml of 0.9% saline solution twice a day.

REMUNOM
ISSN 2178-6925

Received: 20/01/2026 - **Accepted:** 07/02/2026
Vol: 02.1
DOI: 10.61164/40077e20
Pages: 1-14

Figure 1. Preoperative imaging exams and initial surgical procedure for biopsy and cystic decompression.

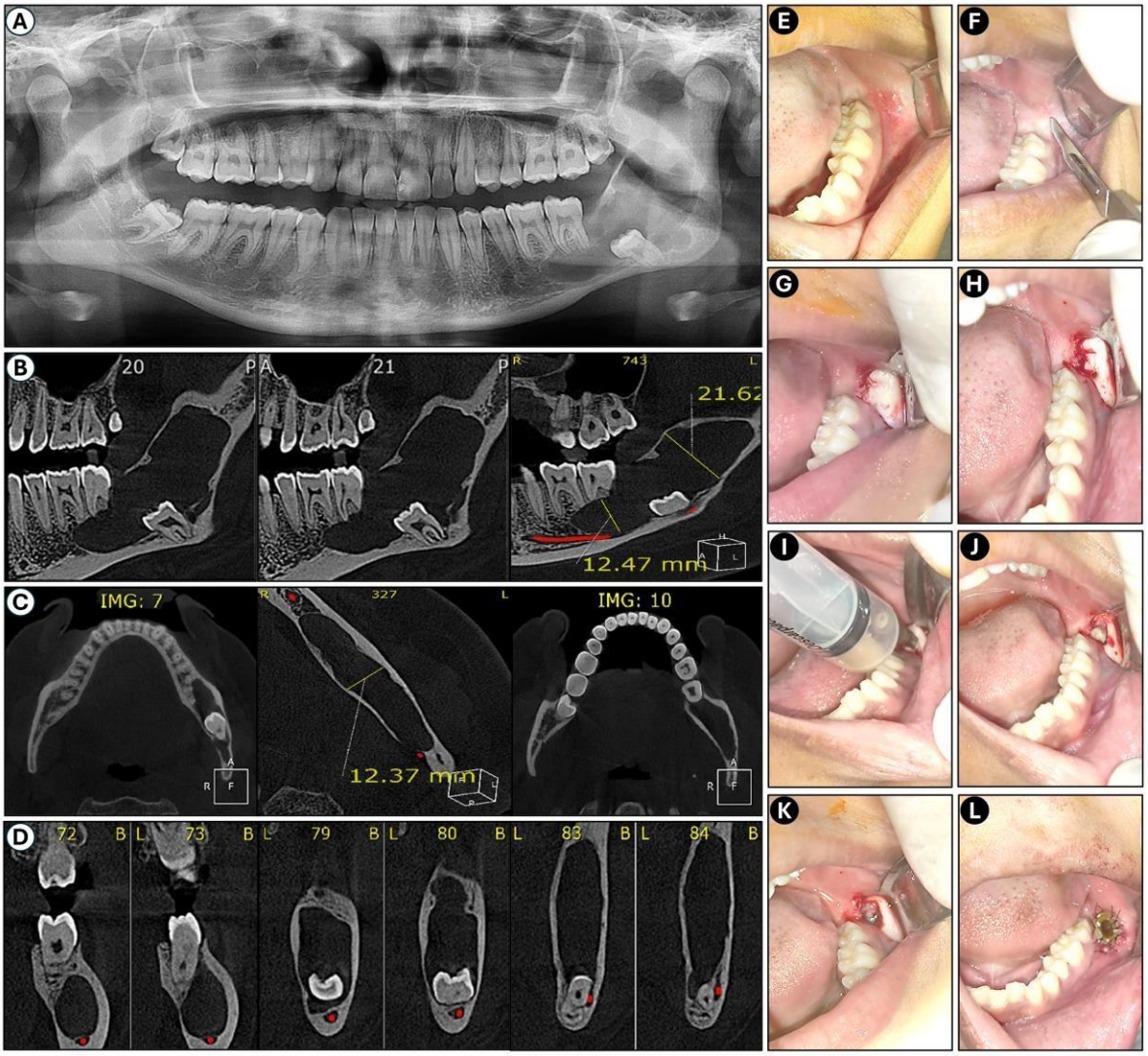

Source: Authors.

Figure 1: Preoperative imaging exams and initial surgical procedure for biopsy and cystic decompression. **A:** Panoramic radiography; **B:** CBCT scan, sagittal plane. **Symbols: Red line -** Path of the inferior alveolar nerve; **C:** CBCT scan, axial plane; **D:** CBCT scan, coronal plane. **Symbols: Red dot -** mandibular canal; **E:** Initial clinical appearance; **F:** Incision; **G:** Detachment of the flap and exposure of bone tissue; **H:** Perforation of the cystic cavity; **I:** Intraosseous puncture; **J:** Osteotomy in the posterior region of the mandible; **K:** Exposure of the cystic cavity and collection of material for biopsy; **L:** Adaptation of the cystic decompression device.

REMUNOM
ISSN 2178-6925

Received: 20/01/2026 - **Accepted:** 07/02/2026
Vol: 02.1
DOI: 10.61164/40077e20
Pages: 1-14

Figure 2. Treatment flowchart with pre- and post-operative steps.

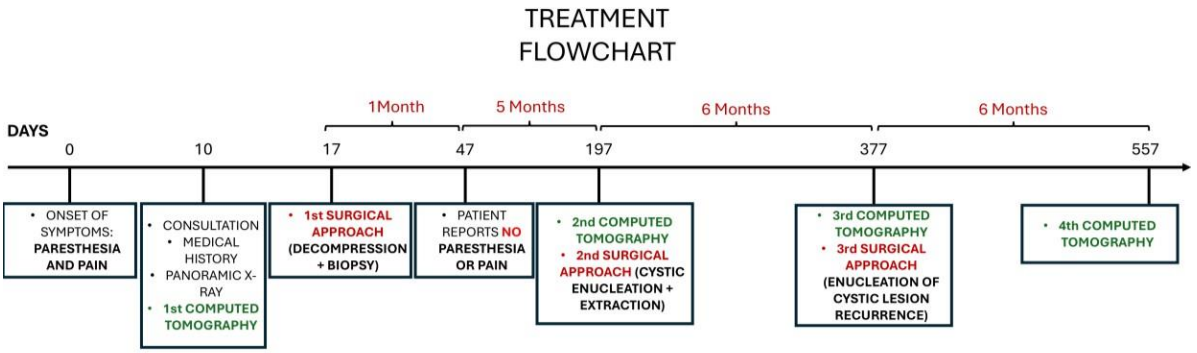

Source: Authors.

The patient remained with the decompression device for 6 months, performing hygiene as instructed and attending periodic consultations every 30 days to evaluate the device. In the first month of decompression, he reported no paresthesia or pain (revealing an evolution from level S2 to level S4 on the Sensory Recovery Scale (MRC), indicating correct decompression of the cyst. Cytopathological analysis revealed that the punctured liquid content consisted of keratinized epithelial cells, some neutrophils and lymphocytes, and red blood cells. Histopathological analysis showed a stratified squamous parakeratinized epithelium, with a predominance of flattened cells on its surface and a keratin layer inside the cavity. the basal layer presented palisaded cells, with a columnar shape and hyperchromatic nuclei and a thin fibrous capsule (Figure 3A, 3B, and 3C). These findings allowed for a definitive diagnosis of OK, confirming the clinical diagnostic hypothesis. After a 6-month decompression period, a new CBCT was requested for follow-up (Figures 4A, 4B, and 4C), revealing a progressive reduction of the cystic cavity and bone neoformation. The sagittal sections (Figure 4B) showed a greater volume of bone at the mandibular base, as well as the movement of tooth 38 to a more superficial position. The coronal sections, in turn (Figure 4C), showed less compression of the mandibular canal and greater thickening of the bone cortices. These tomographic findings confirmed the regression of the cystic lesion, reducing the risks of pathological fracture and damage to noble anatomical structures, such as the inferior alveolar nerve.

REMUNOM
ISSN 2178-6925

Received: 20/01/2026 - **Accepted:** 07/02/2026
Vol: 02.1
DOI: 10.61164/40077e20
Pages: 1-14

Figure 3. Histopathological analysis of odontogenic keratocyst.

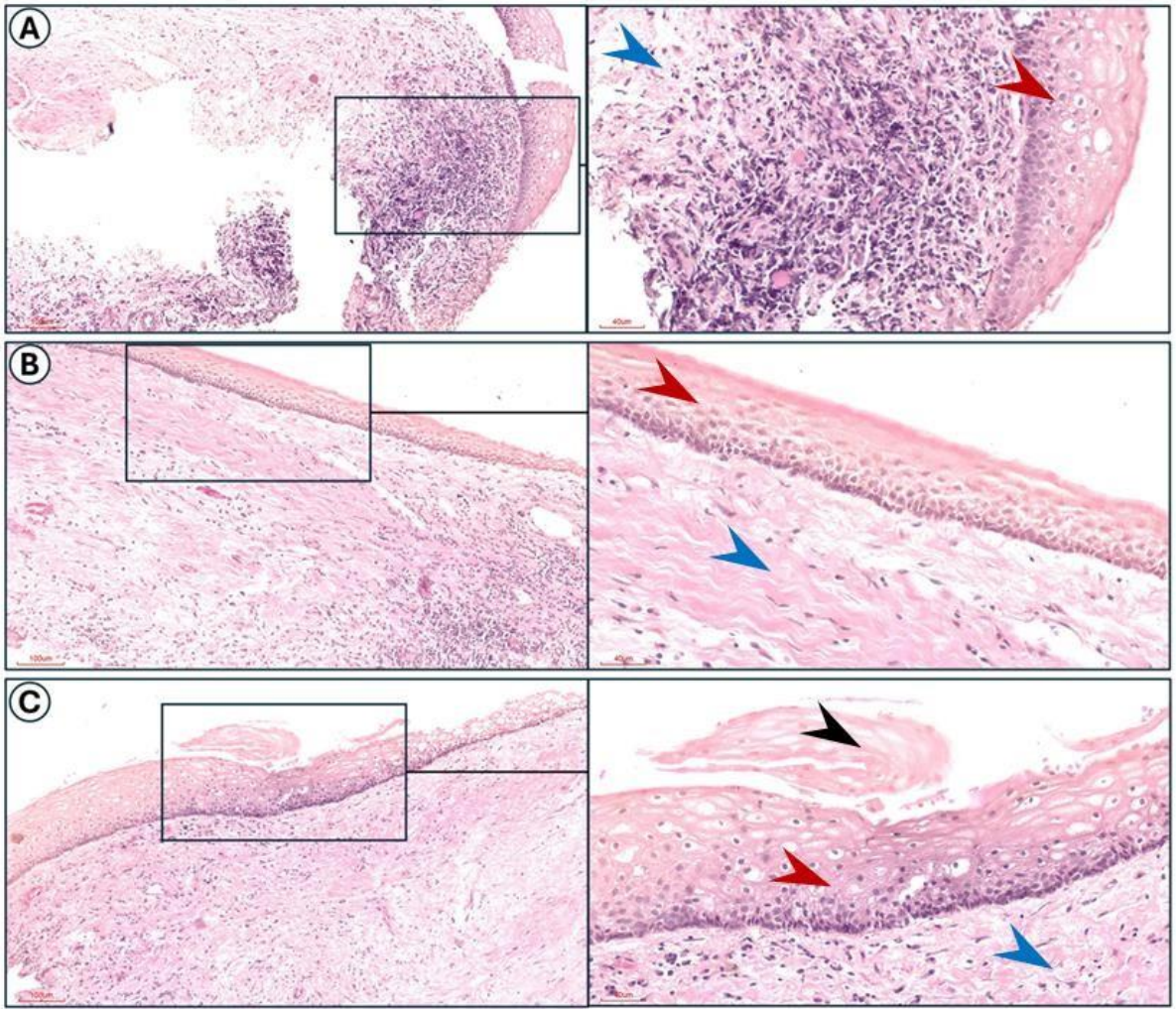

Source: Authors.

Figure 3: Histopathological analysis of odontogenic keratocyst. **A**, **B**, and **C**: photomicrographs of different regions at 100µm and 40µm magnification. **Symbols: Red arrow** - Stratified squamous parakeratinized epithelium; **Blue arrow** - Connective tissue forming the fibrous capsule; **Black arrow** - Keratin lamella.

Cystic enucleation and extraction of tooth 38 were indicated in a second surgical approach. Asepsis and anesthesia were performed to remove the cystic decompression device, followed by a rectilinear incision over the mandibular oblique line (Figure 4D and 4E). The mucoperiosteal flap was folded back and the bone tissue was exposed to perform a new osteotomy to expose the impacted tooth 38 (Figure 4F and 4G). Next, sectioning and extraction were performed, followed by cyst enucleation (Figure 4H and 4I). Bleeding from the cavity was

REMUNOM
ISSN 2178-6925

Received: 20/01/2026 - **Accepted:** 07/02/2026
Vol: 02.1
DOI: 10.61164/40077e20
Pages: 1-14

stimulated to allow for satisfactory blood clot formation, and the mucoperiosteal flap was repositioned with interrupted simple sutures using 4-0 absorbable polyglycolic acid thread (Figure 4J and 4K). No adjuvant solutions were used in conjunction with the surgical procedure. The same medications as in the first surgical approach were prescribed, maintaining the dosage. The patient received guidance and remained under outpatient follow-up, returning every 30 days.

Figure 4. CBCT scan of the mandible after 6 months of decompression and surgical approach for cystic enucleation and tooth extraction.

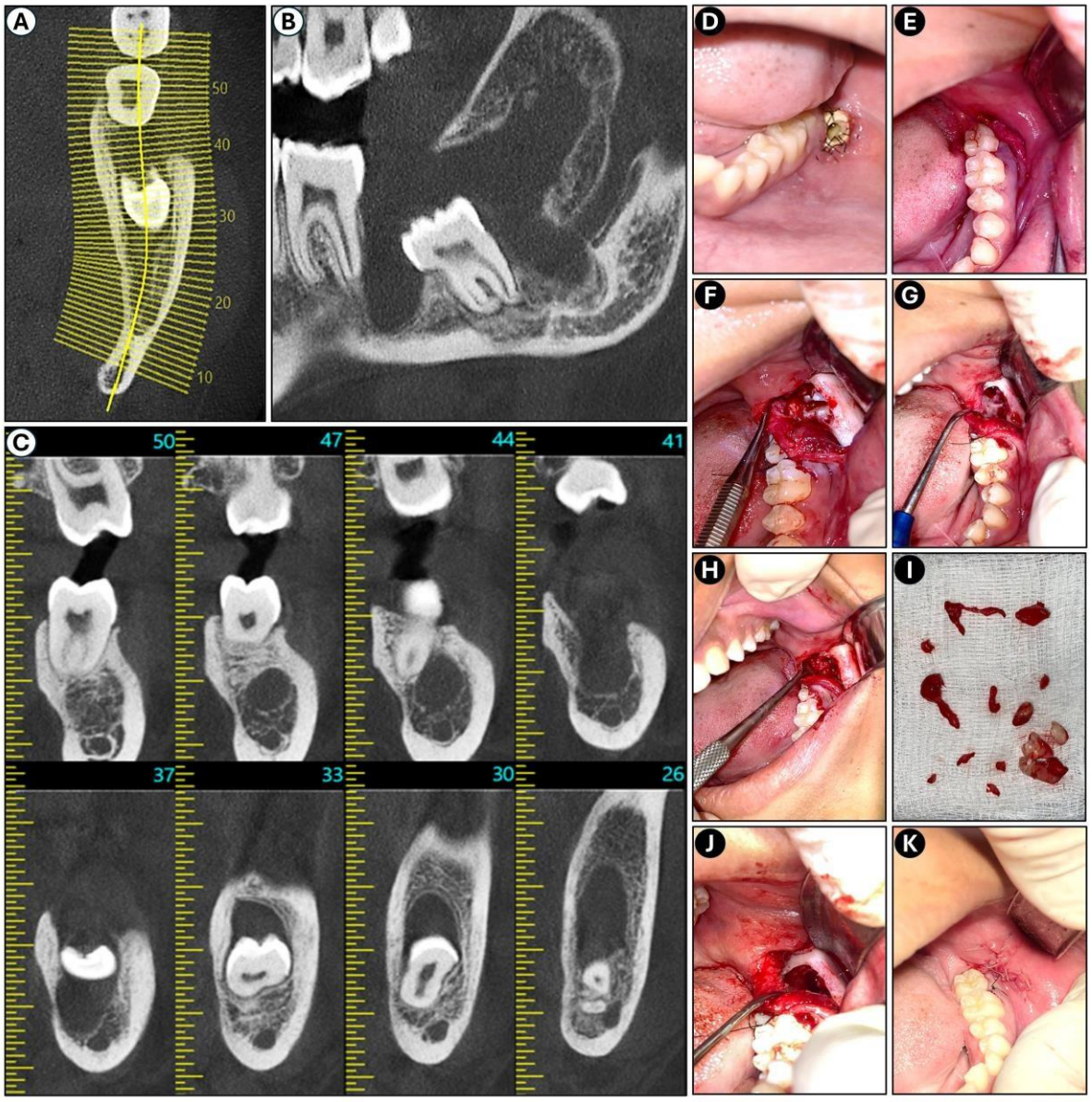

Source: Authors.

REMUNOM
ISSN 2178-6925

Received: 20/01/2026 - **Accepted:** 07/02/2026
Vol: 02.1
DOI: 10.61164/40077e20
Pages: 1-14

Figure 4: CBCT scan of the mandible after 6 months of decompression and surgical approach for cystic enucleation and tooth extraction. **A:** Axial plane with markings of the coronal cuts performed; **B:** Sagittal plane; **C:** Coronal plane. **D:** Appearance of the cystic decompression device in function; **E:** Removal of the cystic decompression device and incision; **F:** Flap reflection and sectioning of tooth 38; **G:** Appearance of the cystic cavity after extraction; **H:** Curettage of the lesion; **I:** Material enucleated and extracted from the cystic cavity; **J:** Final appearance after enucleation and extraction; **K:** Repositioning of the flap with 4-0 polyglycolic acid suture.

After 6 months, a new CBCT was requested for follow-up (Figures 5A, 5B, and 5C), revealing satisfactory bone neoformation. However, a lesion that appeared to be a recurrence of the KO occurred near the root of tooth 37, measuring approximately 10.5 mm x 6.5 mm, revealing the need for a third surgical approach for complete enucleation of the lesion. The surgical procedure began similarly to the previous approaches, with asepsis of the surgical field and anesthesia. The tissue was removed, and it was possible to observe the previous scar areas (Figure 5D). A low biangular incision was made, the mucoperiosteal flap was detached, the bone tissue was exposed, and an osteotomy was performed, allowing exposure of the lesion (Figure 5E), which was enucleated with the aid of specific curettes (Figure 5F). Finally, the cavity was irrigated with 0.9% saline solution (Figure 5G), without the use of adjuvant solutions for irrigation of the surgical site, and the flap was repositioned and stabilized with interrupted simple sutures (Figure 5H). The patient received postoperative instructions and medication prescriptions. At the 30-day postoperative follow-up, clinically satisfactory healing of the soft tissues was observed (Figure 5I), and a pulp sensitivity test performed on elements 37 and 36 revealed that they had preserved pulp vitality.

Six months after the third surgical intervention for enucleation of the cystic lesion recurrence, a CBCT was requested again for follow-up (Figures 5J, 5K, and 5L), which showed complete bone neoformation in the region, with no signs of recurrence. The patient had no clinical changes or complaints such as paresthesia and pain (and remained at level S4 on the Sensory Recovery Scale (MRC)), teeth 36 and 37 maintained pulp vitality without the need for endodontic treatment, and the anatomical structures remained preserved. The patient remains under

REMUNOM
ISSN 2178-6925

Received: 20/01/2026 - **Accepted:** 07/02/2026
Vol: 02.1
DOI: 10.61164/40077e20
Pages: 1-14

quarterly follow-up.

Figure 5. CBCT scan of the mandible 6 months after cystic enucleation and tooth extraction, surgical approach for enucleation of cystic lesion recurrence, and CBCT scan of the mandible 6 months after enucleation of cystic lesion recurrence.

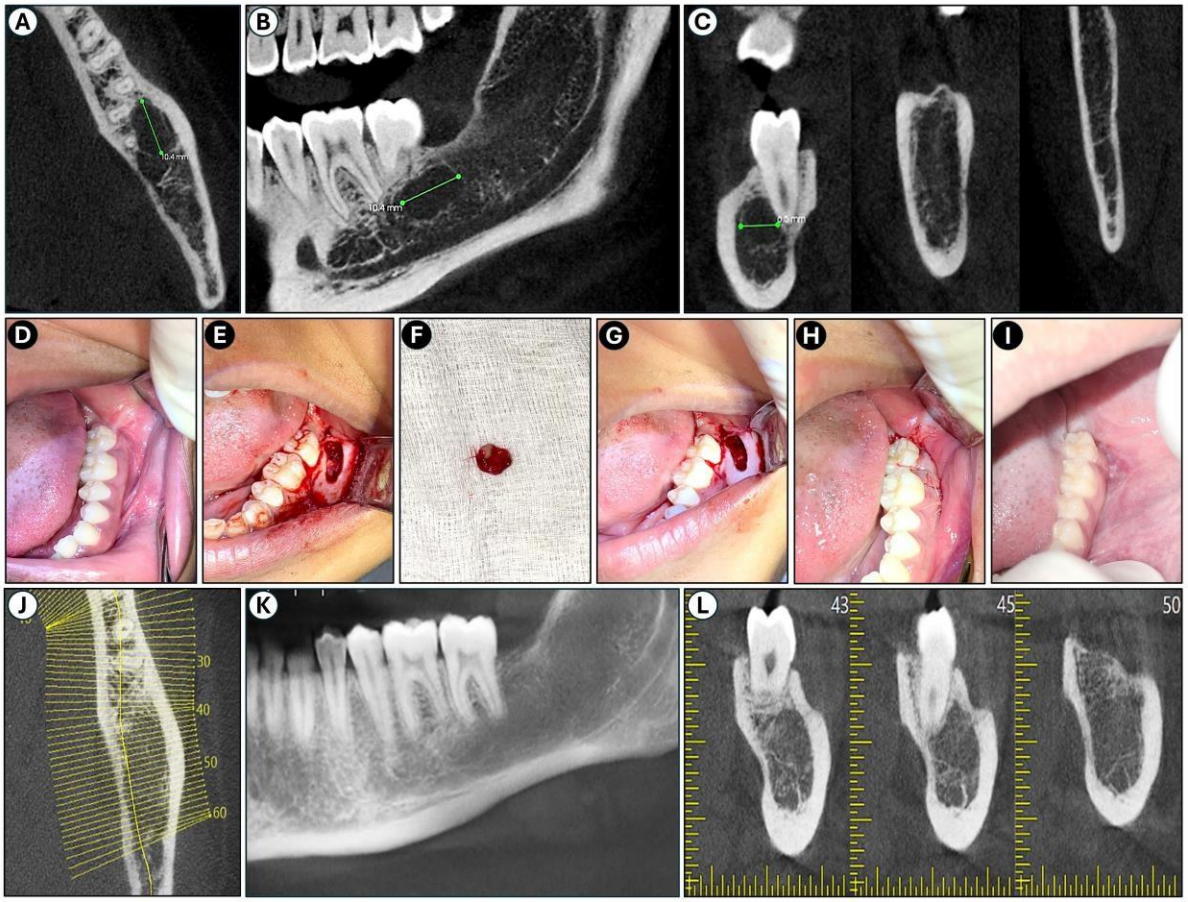

Source: Authors.

Figure 5: CBCT scan of the mandible 6 months after cystic enucleation and tooth extraction, surgical approach for enucleation of probable cystic lesion recurrence, and CBCT scan of the mandible 6 months after enucleation of cystic lesion recurrence. **A:** Axial plane; **B:** Sagittal plane; **C:** Coronal plane. **Symbols: Green line** - delimitation of lesion recurrence. **D:** Initial appearance; **E:** Exposure of the lesion; **F:** Cystic enucleation; **G:** Final appearance after enucleation; **H:** Repositioning and stabilization of the flap with 4-0 polyglycolic acid thread; **I:** Clinical scar appearance after 30 days. **J:** Axial plane with demarcations of the coronal sections performed; **K:** Sagittal plane; **L:** Coronal plane.

REMUNOM
ISSN 2178-6925

Received: 20/01/2026 - **Accepted:** 07/02/2026
Vol: 02.1
DOI: 10.61164/40077e20
Pages: 1-14

4. Discussion

In everyday clinical practice, OK is usually recognized incidentally, in panoramic radiographs or CBCTs requested for unrelated reasons. Signs such as pain, swelling, or paresthesia, when present, tend to indicate larger size or proximity to vital structures (Borghesi *et al.,* 2018; Gupta *et al.,* 2020; Mohamed *et al.,* 2023). This silent behavior helps explain diagnostic delays and reinforces the importance of systematic reading of retromolar regions and the mandibular branch in imaging exams (Borghesi *et al.,* 2018). In the clinical case presented, the presence of paresthesia in the inferior alveolar nerve region, associated with an extensive multilocular lesion overlapping the mandibular canal, reinforced the character of greater local aggressiveness, justifying the need to request and evaluate the CBCT exam to assess the risk of postoperative paresthesia (Liu; Zhou; Huang, 2024). In such cases, two-stage surgical strategies tend to reduce morbidity without compromising local control; in small, well-defined lesions, direct enucleation remains a valid option (de Freitas Gonçalves *et al.,* 2024; Dioguardi *et al.,* 2024; Esonu *et al.,* 2023).

It is important to note that the WHO review and update (5th ed., 2022) reinforce the need to integrate molecular/biological findings with clinical presentation to stratify risk and guide treatment, especially when there are signs that may indicate more proliferative behavior (e.g., extensive involvement, previous recurrence, or association with syndromes) (Gomes *et al.,* 2023).

In the case in question, the decision to perform initial decompression was motivated by the close proximity of the cystic capsule to the mandibular canal, trabecular bone thinning, and increased risk of pathological fracture—decisions supported by evidence demonstrating reduced neurosensory morbidity and improved cortical thickening after decompression, facilitating safer subsequent enucleation (Jianfeng *et al.,* 2024).

Pathological fractures of the mandible are defined as fractures that occur when bone has been weakened by an underlying pathologic process, and although they account for a small percentage of mandibular fractures, they may be facilitated by expansive cystic lesions that lead to peripheral bone resorption and

REMUNOM
ISSN 2178-6925

Received: 20/01/2026 - **Accepted:** 07/02/2026
Vol: 02.1
DOI: 10.61164/40077e20
Pages: 1-14

significant cortical thinning, thereby compromising mechanical integrity (Xiao et al., 2018; Chatziantoniou et al., 2025). Large cystic jaw lesions have been associated with extensive bone destruction and reduced mandibular resistance, which increases the risk of spontaneous or trauma-related pathological fracture when the remaining cortical bone is diminished (Irimia et al., 2021). Moreover, case series and literature reviews document instances of dentigerous and other odontogenic cysts resulting in pathological mandibular fractures when the lesion reaches considerable size and undermines the cortex (Custódio et al., 2021), supporting the notion that extensive mandibular cysts with pronounced cortical thinning represent a plausible clinical risk factor for pathological fracture and justify a staged decompression approach prior to definitive surgical management.

Conservative techniques involve adherence to irrigation/hygiene of the device and longer total time, with a risk of canal closure; on the other hand, direct approaches shorten treatment but can increase morbidity when there is marked cortical thinning or contact with the IAN (Dioguardi *et al.,* 2024; Esonu *et al.,* 2023).

More recent reports and case series (2020–2024) indicate that decompression/marsupialization, when well conducted, produces significant volumetric reduction and improvement in bone density within months, which justifies the choice by many professionals. However, it is crucial to discuss with the patient the increased treatment time and the possibility of the need for a second intervention (Liu; Zhou; Huang, 2024; Caminiti *et al.,* 2021). In the present case report, the patient's adherence to the decompression protocol was adequate, a fact that increases the likelihood of satisfactory bone remodeling and less traumatic enucleation in the next stage.

The criteria for the duration of decompression and the transition to definitive enucleation are primarily guided by both clinical and radiographic indicators of bone remodeling and lesion regression. According to recent literature, the transition is typically considered when there is sufficient cortical thickening, reduction in lesion volume, and decreased proximity to critical structures such as the inferior alveolar nerve (Caminiti et al., 2021; Liu, Zhou, Huang, 2024). Periodic

REMUNOM
ISSN 2178-6925

Received: 20/01/2026 - **Accepted:** 07/02/2026
Vol: 02.1
DOI: 10.61164/40077e20
Pages: 1-14

CBCT or panoramic imaging, generally performed every 1–3 months during decompression, allows for objective monitoring of bone neoformation, reduction of lesion dimensions, and stabilization of the cystic cavity. Clinically, absence of pain, resolution or improvement of paresthesia, and stable soft tissue conditions are also used as markers to proceed safely to enucleation (Dioguardi et al., 2024; Esonu et al., 2023). This staged approach balances the benefits of conservative bone remodeling with the risk of prolonged treatment, ensuring that the mandible has regained sufficient mechanical resistance before definitive surgical intervention, thereby minimizing the risk of pathological fracture and nerve injury.

Regarding the lesion near the root of tooth 37, histopathological confirmation was not performed, which is a limitation of this report. Although the radiographic appearance suggested recurrence, clinical and imaging follow-up allowed careful monitoring and timely management.

Regardless of the strategy, prolonged surveillance is mandatory. Studies suggest that most recurrences emerge within the first five years, during which periodic clinical and radiographic checks are recommended (Esonu *et al.,* 2023). Thus, six-monthly follow-up with panoramic radiography or CBCT is recommended during the first year after treatment, followed by annual follow-up for at least 5 years. For high-risk lesions, some authors suggest annual imaging controls in the first 5 years, followed by controls every 2 years, seeking to balance early detection and control of patient exposure to radiation (Winters *et al.,* 2023).

5. Conclusion

It is concluded that conservative treatment, consisting of decompression followed by surgical enucleation, was effective for the treatment of extensive mandibular OK, preventing the risk of pathological fracture and treating the initial pathology, recurrence, and its consequences, such as pain and paresthesia.

References

SOLUK-TEKKESIN, M.; WRIGHT, J. M. The World Health Organization classification of odontogenic lesions: a summary of the changes of the 2022 (5th) edition. Head and Neck Pathology, v. 16, n. 1, p. 123–143, 2022. DOI: 10.1007/s12105-021-01338-x.

REMUNOM
ISSN 2178-6925

Received: 20/01/2026 - **Accepted:** 07/02/2026
Vol: 02.1
DOI: 10.61164/40077e20
Pages: 1-14

BORGHESI, A. et al. Odontogenic keratocyst: imaging features of a benign lesion with an aggressive behaviour. Insights into Imaging, v. 9, p. 883–897, 2018. DOI: 10.1007/s13244-018-0644-z.

DE FREITAS GONÇALVES, T. O. et al. Management and recurrence of the odontogenic keratocyst: an overview of systematic reviews. Oral and Maxillofacial Surgery, v. 28, n. 4, p. 1457–1478, 2024. DOI: 10.1007/s10006-024-01277-4.

GUPTA, S. et al. CBCT in the evaluation of odontogenic lesions: a review with special reference to keratocyst. Journal of Oral Biology and Craniofacial Research, v. 10, n. 3, p. 171–178, 2020. DOI: 10.1016/j.jobcr.2020.06.007.

XIAO X, DAI J-W, Il Z, ZHANG W. Pathological fracture of the mandible caused by radicular cyst: a case report and literature review. Medicine (Baltimore). 2018;97(50):e13529.

CHATZIANTONIOU G, et al. Pathological fractures of the mandible: imaging and etiologic considerations. Diagnostics. 2025;15(10):1216.

IRIMIA A, et al. Minimally invasive two-staged surgery in the treatment of large cystic lesions of the jaw. Healthcare (Basel). 2021;9(11):1531.

CUSTÓDIO GP, et al. Pathological mandible fracture related to cystic lesion. RSD Journal. 2021.

DIOGUARDI, M. et al. Factors and management techniques in odontogenic keratocysts: a systematic review. European Journal of Medical Research, v. 29, n. 1, p. 287, 2024. DOI: 10.1186/s40001-024-01854-z.

JACOBS, T. et al. Comparing 5-fluorouracil versus modified Carnoy's solution for the treatment of odontogenic keratocysts: a systematic review and meta-analysis. Journal of Oral and Maxillofacial Surgery, v. 82, n. 11, p. 1433–1440, 2024. DOI: 10.1016/j.joms.2024.06.181.

ESONU, O. K. et al. What is the 5-year incidence of recurrent disease for odontogenic keratocyst? A time-to-event analysis. Journal of Oral and Maxillofacial Surgery, v. 81, n. 2, p. 226–234, 2023.

REMUNOM
ISSN 2178-6925

Received: 20/01/2026 - **Accepted:** 07/02/2026
Vol: 02.1
DOI: 10.61164/40077e20
Pages: 1-14

MOHAMED, A. A. et al. Odontogenic keratocysts: presentation and surgical management — a 10-year experience. Cureus, v. 15, n. 8, e43306, 2023.

DONNELLY, L. A. et al. Modified Carnoy's compared to Carnoy's solution is associated with increased recurrence of odontogenic keratocysts. Journal of Oral and Maxillofacial Surgery, v. 79, n. 8, p. 1670–1680, 2021.

LIU, H.; ZHOU, N.; HUANG, X. The application of wing-shaped window decompression device in the treatment of large odontogenic keratocyst: an observational study. Medicine (Baltimore), v. 103, n. 36, e39601, 2024. DOI: 10.1097/MD.0000000000039601.

GOMES, I. P. et al. The molecular basis of odontogenic cysts and tumours. Journal of Oral Pathology & Medicine, v. 52, n. 4, p. 351–356, 2023. DOI: 10.1111/jop.13401.

HE, J.; WANG, H.; ZENG, J.; ZHOU, L. Large mandibular odontogenic keratocyst treated by decompression and secondary enucleation: a case report. Journal of Clinical Pediatric Dentistry, v. 48, n. 6, p. 213–220, 2024.

CAMINITI, M. F. et al. 5-fluorouracil is associated with a decreased recurrence risk in odontogenic keratocyst management: a retrospective cohort study. Journal of Oral and Maxillofacial Surgery, v. 79, n. 4, p. 814–821, 2021. DOI: 10.1016/j.joms.2020.07.215.

WINTERS, R. et al. Safety and efficacy of adjunctive therapy in the treatment of odontogenic keratocyst: a systematic review. British Journal of Oral and Maxillofacial Surgery, v. 61, n. 5, p. 331–336, 2023. DOI: 10.1016/j.bjoms.2023.04.006.