REMUNOM
ISSN 2178-6925

Received: 20/04/2026 - **Accepted:** 25/05/2026
Vol: 13.11
DOI: 10.66104/50etnh37
Pages: 1-38

SYSTEMIC PLATELET-RICH PLASMA (S-PRP) AS AN ADJUVANT IN THE TREATMENT OF FELINE AZOTEMIA: AN EXPLORATORY CASE SERIES

PLASMA RICO EM PLAQUETAS SISTÊMICO (S-PRP) COMO ADJUVANTE NA TERAPÊUTICA DA AZOTEMIA FELINA: SÉRIE DE CASOS EXPLORATÓRIA

SYSTEMIC PLATELET-RICH PLASMA (S-PRP) AS A COADYUVANT IN THE TREATMENT OF FELINA AZOTEMIA: A SERIES OF EXPLORATORY CASES

Flavia Gill Ricco
Veterinarian, Apex Vet Medicina Veterinaria Ltda, Brazil
Email: flavia.ricco@gmail.com

Domingos Savio de Aquino Junior
Veterinarian, Apex Vet Medicina Veterinaria Ltda, Brazil
Email: domingos_aquino@hotmail.com

Maira Mendonca Braz de Andrade
Veterinarian, Bioferas Clinica Veterinaria, Brazil
Email: mairambraz@gmail.com

Abstract

Feline kidney disease is an important multifactorial disease, frequently associated with tubulointerstitial inflammation, fibrosis, and progressive reduction of renal function. Considering the lack of established regenerative therapies in veterinary medicine, this study aimed to report the use of systemic platelet-rich plasma (S-PRP) as an adjuvant therapy to conventional treatment in three cats with azotemia and clinical alterations compatible with renal dysfunction. Patients underwent fluid therapy and conventional clinical support combined with S-PRP administration. Clinical, laboratory, and ultrasonographic parameters were evaluated before and after the intervention. Clinical improvement was observed, characterized mainly by return of appetite, reduction of nausea, and clinical stabilization, accompanied by a reduction in serum creatinine and urea levels to varying degrees among the evaluated cases. No patient presented adverse effects related to the application of S-PRP during the follow-up period. Despite methodological limitations, the findings suggest potential application of S-PRP as adjuvant therapy in cats with renal dysfunction, reinforcing the need for controlled and standardized studies to evaluate its efficacy and safety.

Keywords: felines, systemic therapy, plasma, regenerative therapy, growth factors, integrative medicine.

REMUNOM
ISSN 2178-6925

Received: 20/04/2026 - **Accepted:** 25/05/2026
Vol: 13.11
DOI: 10.66104/50etnh37
Pages: 1-38

Resumo

A doença renal felina constitui importante enfermidade de caráter multifatorial, frequentemente associada à inflamação túbulo-intersticial, fibrose e redução progressiva da função renal. Considerando a ausência de terapias regenerativas consolidadas na medicina veterinária, o presente trabalho teve como objetivo relatar o uso do plasma rico em plaquetas sistêmico (S-PRP) como terapia adjuvante ao tratamento convencional em três felinos com azotemia e alterações clínicas compatíveis com disfunção renal. Os pacientes foram submetidos à fluidoterapia e suporte clínico convencional associados à administração de S-PRP. Foram avaliados parâmetros clínicos, laboratoriais e ultrassonográficos antes e após a intervenção. Observou-se melhora clínica caracterizada principalmente por retorno do apetite, redução de náusea e estabilização clínica, acompanhada por redução dos níveis séricos de creatinina e ureia em diferentes graus entre os casos avaliados. Nenhum paciente apresentou efeitos adversos relacionados à aplicação do S-PRP durante o período de acompanhamento. Apesar das limitações metodológicas, os achados sugerem potencial aplicação do S-PRP como terapia adjuvante em felinos com disfunção renal, reforçando a necessidade de estudos controlados e padronizados para avaliação de sua eficácia e segurança.

Palavras-chave: felinos, terapia sistêmica, plasma, terapia regenerativa, fatores de crescimento, medicina integrativa.

Resumen

Feline kidney disease is a significant multifactorial condition, frequently associated with tubulointerstitial inflammation, fibrosis, and progressive decline in renal function. Given the lack of established regenerative therapies in veterinary medicine, this study aimed to report on the use of systemic platelet-rich plasma (S-PRP) as an adjunct to conventional treatment in three cats with azotemia and clinical signs consistent with renal dysfunction. Patients received fluid therapy and conventional clinical support combined with S-PRP administration. Clinical, laboratory, and ultrasound parameters were evaluated before and after the intervention. Clinical improvement was observed, characterized primarily by a return of appetite, a reduction in nausea, and clinical stabilization, accompanied by varying degrees of reduction in serum creatinine and urea levels among the evaluated cases. No patients experienced adverse effects related to S-PRP administration during the follow-up period. Despite methodological limitations, the findings suggest a possible application of PRP-S as adjuvant therapy in cats with renal dysfunction, reinforcing the need for controlled and standardized studies to evaluate its efficacy and safety.

Keywords: felines, systemic therapy, plasma, regenerative therapy, growth factors , integrative medicine.

REMUNOM
ISSN 2178-6925

Received: 20/04/2026 - **Accepted:** 25/05/2026
Vol: 13.11
DOI: 10.66104/50etnh37
Pages: 1-38

1. Introduction

Renal diseases in felines represent a highly prevalent illness in small animal clinics, especially in animals over seven years old. Their etiology is multifactorial and includes congenital nephropathies, glomerulonephritis, chronic pyelonephritis, nephrosclerosis, lithiasis, and other causes, resulting in tubulointerstitial inflammation, tubular atrophy, and interstitial fibrosis, with progressive reduction of renal function in case of chronic kidney disease. These diseases can be reversible, with pronounced symptoms and rapid progression in acute kidney injury (AKI), or have a mixed character, more commonly, where acute lesions culminate in permanent renal damage or in chronic cases considered exacerbated, due to the loss of homeostasis achieved even outside reference parameters (POLZIN, 2011; BROWN *et al* ., 2016).

Clinically, it is characterized by polyuria, polydipsia, weight loss, anorexia, and uremic signs in advanced stages, negatively impacting the quality of life of affected animals (IRIS, 2024), with azotemia being a common symptom of various causes, requiring constant and prolonged monitoring and the performance of complementary tests for its correct diagnosis.

Currently, there is no definitive treatment in veterinary medicine. Conventional approaches aim to treat the primary cause of kidney damage, and other conservative therapies aim to alleviate the symptoms of the disease and include specific diets, prolonged drug therapy, pain control, and vitamin and mineral supplementation. They rely on the control of biochemical parameters to stage its progression, but do not act directly on tissue regeneration (ANDERSON; RENNEKE; BRENNER, 1986). Fluid therapy deserves special mention in this context since it acts directly on biochemical markers by hydrating the patient, acting on one of the symptoms with repercussions in various metabolic pathways, helping to restore the body's homeostasis. In this context, adjuvant therapies that promote quality of life and well-being through inflammation modulation are of great interest in feline medicine (VENDRUSCOLO *et al* ., 2018) and in humans (OLSZEWER; ARROYO; NAKAMURA, 2015).

2. Literature Review

Treatment for cats suffering from kidney disease focuses on controlling electrolyte imbalances and alleviating symptoms.

REMUNOM
ISSN 2178-6925

Received: 20/04/2026 - **Accepted:** 25/05/2026
Vol: 13.11
DOI: 10.66104/50etnh37
Pages: 1-38

The main therapeutic strategies for treating kidney disease include differentiated dietary management, electrolyte supplementation, endocrine replacement, hydration, and stimulation of metabolite excretion, with the intention of correcting alterations due to excesses or deficiencies, thus minimizing symptoms (EVANGELISTA, 2023).

Considering hydration as a parameter of broad influence on homeostasis mechanisms as well as on the patient's well-being, the importance and results obtained with fluid therapy should be considered . This therapeutic modality is necessary because felines are sometimes unable to maintain adequate hydration levels orally, making intravenous or subcutaneous administration necessary (EVANGELISTA, 2023). Therapies for specific symptoms seem to demonstrate clinical response, such as calcium channel blockers for controlling blood pressure and proteinuria, and protein and phosphate restriction in the diet. These treatments should be maintained under continuous monitoring until the condition resolves or when the patient is able to return home. (EVANGELISTA, 2023).

Blood is the body tissue present in the circulatory system, composed of three cell types: red blood cells, white blood cells, and platelets, all surrounded by plasma. Platelets play a fundamental role, acting directly in hemostasis and wound healing through the release of granules rich in growth factors involved in mitogenesis, angiogenesis, and cellular chemotaxis (HUNTINGFORD *et al* ., 2024; LANA *et al* ., 2025).

Platelet-rich plasma (PRP) is an autologous concentrate of platelets that, upon activation, release granules rich in growth factors such as platelet-derived growth factor (PDGF), transforming growth factor beta (TGF-β), vascular endothelial growth factor (VEGF), insulin-like growth factor 1 (IGF-1), and modulating cytokines. According to LANA *et al* . (2025), in humans, the growth factors released after platelet activation stimulate angiogenesis, cellular chemotaxis, inflammatory modulation, and tissue repair, where platelets are attracted to areas of injury, a mechanism known as " homing ," and play an important role in initiating the process that culminates in tissue regeneration in an attempt to prevent fibrosis, two different forms of tissue repair.

Although PRP is increasingly used in orthopedics and wound healing (VENDRUSCOLO *et al* ., 2018), its systemic use in humans, described by Olszewer , Arroyo and Nakamura (2015) in the treatment of chronic-degenerative diseases, has not been specifically described in CKD in people or animals, even though it is based

REMUNOM
ISSN 2178-6925

Received: 20/04/2026 - **Accepted:** 25/05/2026
Vol: 13.11
DOI: 10.66104/50etnh37
Pages: 1-38

on the biochemical effect and significant therapeutic potential documented in other pathologies, especially in orthopedics and dentistry.

Although there are no treatments that correct the lesions of CKD, the search for ways to slow its progression through supportive treatments and therapies, such as the conventional therapies mentioned here, paves the way for integrative therapies applied concurrently, seeking to enhance results.

3. Methodology

The present study aimed to report the use of S-PRP as an adjuvant therapy in conventional feline treatment in an exploratory case series, demonstrating qualitative clinical benefits as well as improvements in biochemical markers.

The methodology was based on clinical evaluation, anamnesis, physical examination, and laboratory tests, making use of the respective bibliographic references, as well as the description of the treatment instituted and the evolution of the general condition supported by subsequent laboratory tests.

For all animals, the same methodology described by Bertoletti et al. (2014) was applied, as described below in the preparation of PRP.

Prior to venous blood collection, the animals underwent trichotomy of the ventral neck region, and antisepsis was performed with a 0.5% chlorhexidine solution in an alcoholic medium. Jugular vein puncture was performed using a vacuum blood collection system with a 21G needle in a sterile tube containing 3.2% sodium citrate, with a volume corresponding to 3.6 ml (1 vial) of blood collected per patient.

The blood was centrifuged immediately after collection in a fixed-angle centrifuge model FL90815A at 400G for 10 minutes, promoting the separation of plasma and red blood cells. After this first centrifugation, all the plasma was removed and placed in a sterile 4ml dry tube using a syringe for a second centrifugation at 600G for 10 minutes in the same centrifuge. After the second centrifugation, the upper two-thirds of the plasma, corresponding to platelet-poor plasma, was discarded, and the final third of the plasma, corresponding to the platelet-rich fraction, was collected using a 1ml syringe attached to a 16G catheter. The final volume was approximately 0.6ml of platelet-rich plasma. Based on the study conducted by Bertoletti et al. (2014), in felines this technique achieved average concentrations more than 22 times the baseline platelet value, exceeding 7,000,000 platelets/µL. In the cases presented here,

REMUNOM
ISSN 2178-6925

Received: 20/04/2026 - **Accepted:** 25/05/2026
Vol: 13.11
DOI: 10.66104/50etnh37
Pages: 1-38

these values ranged between 2,120,000/µL and 2,420,000/µL. The estimated count was performed on the smear, with 20 µL collected from the final product. This technique consisted of counting platelets on a microscope slide stained with GiENSA, where the average number of platelets in 10 microscopy fields visualized in the stained smear using a 100x objective on a Biofocus® optical microscope was calculated. This calculated average value was multiplied by 15,000, resulting in the estimated number of platelets per microliter. This technique is simpler, but less precise than counting in a Neubauer chamber. The decision was made not to activate the platelets since this activation process begins as soon as the blood is drawn and can be accelerated by altering the medium in which they are inserted. Considering that their purpose is to be diluted in an isotonic solution and administered intravenously, it is advantageous not to add substances to the preparation, providing greater safety by reducing product handling.

For application, the collected platelet concentrate was diluted in a sterile bag of 0.9% isotonic sodium chloride solution containing a solution volume equivalent to 10 ml/kg of the patient's weight. The solution containing the diluted platelet-rich plasma fraction was administered intravenously to patients via peripheral venous access, in the cephalic vein of the right thoracic limb, using a 24G catheter and macrodrip infusion set, with a calculated flow rate of 4 ml/kg/hour, taking approximately 2.5 hours for complete infusion. During this time, patient parameters were monitored using an SDAMED® SDA3 multiparameter monitor, and no local or systemic reactions such as pain, fever, sneezing, itching, vomiting, hemodynamic instability, or alterations in consciousness or behavior were observed. This methodology, combining the preparation of platelet-rich plasma and the intravenous administration of its dilution, is called S-PRP to facilitate the flow of reports.

4. Results and Discussion

Case 1 - Feline-1, female, mixed breed, 13 years old, (+) FIV. Main complaint: anorexia. Physical examination (Table 1), laboratory tests (Table 2) and urinalysis (Table 3).

REMUNOM
ISSN 2178-6925

Received: 20/04/2026 - **Accepted:** 25/05/2026
Vol: 13.11
DOI: 10.66104/50etnh37
Pages: 1-38

Table 1. Physical Examination - Feline 1

Score	Weight (kg)	Dehydration (%)	TPC (sec)	PAS (mmHg)
2	2.46	5 - 6	2	178

The animal presents with a low body condition score, dehydration, and increased blood pressure .

Source: Authors (2026).

Management: Following anamnesis during a consultation on September 12th, the cat was hospitalized for 4 days, receiving intravenous fluid therapy (lactated Ringer's solution 50ml/kg/day), antiemetic (ondansetron 0.5mg/kg every 8 hours intravenously and maropitam 1mg/kg every 24 hours subcutaneously), aluminum hydroxide (20mg/kg) every 8 hours orally along with enteral feeding, and the appetite stimulant mirtazapine (2mg/cat) every 48 hours. The cat recovered from dehydration and the vomiting episodes ceased, but lacked appetite and remained nauseous. On the 5th day of hospitalization (September 16th), S-PRP was administered according to the protocol described in this study, a single application, and a blood sample was collected for feline serum amyloid A measurement to monitor the patient's progress. After 48 hours of S-PRP administration combined with multimodal clinical management... (September 18th), while maintaining conventional therapy, a new blood sample was taken to evaluate biochemical and hematological parameters. The patient showed improved appetite, resuming feeding on its own, without episodes of vomiting or nausea. It was discharged and continued with home treatment with Cerenia® once a day orally (¼ of a 16mg tablet) for 3 days. After 7 days (September 25th), a new control examination was performed to assess the animal's progress, which remained clinically stable as shown in Table 2, without the need for further intervention.

Table 2. Biochemical and hematological parameters of feline 1.

Pre S-PRP			**Post S-PRP**			
Parameter	**12/09/25**	**16/09/25**	**18/09/25**	**25/09/25**	**17/02/26**	**Reference**
Creatinine (mg/ dL)	4.9		3.2	2.7	2.9	0.5 to 1.7
Urea (mg/ dL)	142.2		114.2	132.8	102.4	20 to 65
Phosphorus (mg/ dL)	10.29		6.57			3.29 to 8.28
Hematocrit (%)	28			19	27	26 to 47
White blood cells /mm3	28,100			15,000	15,000	5,500 to 19,500
Platelets / mm3	168,000			328,000	349,000	100,000 to 518,000

REMUNOM
ISSN 2178-6925

Received: 20/04/2026 - **Accepted:** 25/05/2026
Vol: 13.11
DOI: 10.66104/50etnh37
Pages: 1-38

Proteins (g/ dL)	10.0		10.0	10.0	8.8	5.3 to 8.6
Albumin	1.6		1.5	2.0	2.7	2.1 to 3.9
Amylase (IU/L)	2.045		846			500 to 1,800
Amyloid A serum (mcg/ mL)		58.4	14.6			<5.0

It is possible to identify increased values of Urea, Creatinine, Phosphorus, Leukocytes, Amylase and plasma proteins (12/09) in addition to the SAA value (16/09) at the beginning of clinical management. Afterwards, it is possible to observe that parameters related to inflammation such as Leukocytes and SAA tend to decrease, in accordance with the animal's clinical condition.

Source: Authors (2026).

Feline Ultrasound 1 – (September 15, 2025, prior to S-PRP application) - Symmetrical kidneys with maintained dimensions, preserved cortical echogenicity and cortical echotexture with preserved corticomedullary relationship . No signs of renal pelvis and ureter dilation. Presence of a 0.3cm lithiasis in the right kidney. Right kidney dimensions 3.3cm and left kidney 3.7cm longitudinal axis (as per report).

The patient in question returned to the clinic on February 17, 2026 (the following year) presenting signs consistent with suspected chronic kidney disease such as polyuria, polydipsia, weight loss, elevated systolic blood pressure, azotemia (Table 2), selective appetite, and an increased urinary protein-to-creatinine ratio (Table 3). However, the lack of systematic follow-up of the case prevents us from confirming that it is the suspected pathology.

Table 3. Feline urinalysis 1.5 months after S-PRP application.

Parameter	17/02/26	Reference
Volume (mL)	2	5
Density	1.008	1.035 to 1060
pH	5.0	6.0 to 7.0
Protein (mg/dl)	100mg	Negative
Bacteria	Rare	Rare
Red blood cells	0 to 1 / field	Up to 5 / field 40x
Leukocytes	3 to 5 / field	Up to 5 / field 40x
PU/CU	2.42	< 0.20

Presence of proteinuria associated with low urine specific gravity. Increased urinary protein-to-creatinine ratio.

Source: Authors (2026).

REMUNOM
ISSN 2178-6925

Received: 20/04/2026 - **Accepted:** 25/05/2026
Vol: 13.11
DOI: 10.66104/50etnh37
Pages: 1-38

The patient remained stable for 5 months without requiring further clinical intervention. Due to the absence of parameters such as SDMA, staging the patient according to the IRIS classification (2024) is not feasible, nor is classifying azotemia as pre-renal , renal, or post-renal. In addition to the analytical and diagnostic limitations, the importance of concomitant clinical management alongside S-PRP must be considered, including fluid therapy, enteral feeding, phosphate binders, appetite stimulants, antiemetics, etc. It is noted that it is impossible to accurately estimate the relevance of this set of care measures independently based on the presented markers, highlighting the importance of multimodal patient management.

Case 2 - feline-2, male, Ragdoll , 13 years old. Physical examination (Table 4), laboratory tests (Table 5).

Table 4. Physical Examination - Feline 2

Score	Weight (kg)	Dehydration (%)	TPC (sec)	PAS (mmHg)
2	3.0	7 - 8	2	160

The animal presents with a low body condition score, dehydration, and increased blood pressure .

Source: Authors (2026).

Management: Following anamnesis during a consultation on August 25th, the patient was hospitalized for 2 days with intravenous fluid therapy using Ringer's lactate (50ml/kg/day), the antiemetic ondansetron (0.5mg/kg) every 8 hours intravenously, maropitan (1mg/kg) every 24 hours subcutaneously, aluminum hydroxide (20mg/kg) every 8 hours orally along with enteral feeding, and the appetite stimulant mirtazapine (2mg) every 48 hours. This did not result in appetite recovery or nausea control. After approximately 48 hours of hospitalization, an S-PRP injection was administered (August 27th) and the aforementioned therapy was maintained. After 48 hours of the procedure, blood was collected for further evaluation of tests. The animal showed recovery of appetite, eating spontaneously, and did not present nausea. This condition was accompanied by improvement in biochemical parameters (Table 5). The patient was discharged to continue home treatment with Cerenia® once a day orally (¼ of a 16mg tablet) for 3 days.

REMUNOM
ISSN 2178-6925

Received: 20/04/2026 - **Accepted:** 25/05/2026
Vol: 13.11
DOI: 10.66104/50etnh37
Pages: 1-38

Table 5. Biochemical and hematological parameters of feline 2.

Pre S-PRP		**Post S-PRP**	
Parameter	**26/08**	**29/08**	**Reference**
Creatinine (mg/ dL)	6.5	2.8	0.5 to 1.7
Urea (mg/ dL)	200.0	138	20 to 65
Phosphorus (mg/ dL)	12.43	4.40	3.29 to 8.28
Hematocrit (%)	31	27	26 to 47
White blood cells /mm3	9,700	9,500	5,500 to 19,500
Platelets / mm3	220,000	230,000	100,000 to 518,000
Proteins (g/ dL)	9.1	7.7	5.3 to 8.6
Albumin	3.1	2.8	2.1 to 3.9

A clear, abrupt increase in Urea, Creatinine, and Phosphorus between July 2nd and August 26th, approximately 55 days.

Source: Authors (2026).

Feline Ultrasound 2 – (02/07/2025 pre -S-PRP) kidneys in usual location, symmetrical, dimensions maintained, elevated cortical echogenicity, with a focal area in the right cortex with differential diagnosis for old renal infarction, cortical echotexture maintained, corticomedullary relationship preserved. No dilation of the renal pelvis and ureters. No signs of lithiasis. Right kidney dimensions 3cm longitudinal axis and left kidney 3.9cm longitudinal axis. As per report.

Feline Ultrasound 2 – (08/26/2025 pre -S-PRP) kidneys in usual location, symmetrical, reduced dimensions in the right kidney. Right kidney dimensions 3cm longitudinal axis, left kidney 4.1 cm longitudinal axis.

Right kidney: elevated cortical echogenicity , preserved cortical echotexture , slight loss of corticomedullary relationship . Loss of morphology, slight dilation of the renal pelvis measuring approximately 0.27 cm. No signs of ureteral dilation and no signs of lithiasis. As per report.

Due to the lack of standardization in the intervals between measurements of biochemical and hematological parameters , as well as the discontinuation of these measurements after the period considered clinical improvement, during which the animal was returned home under the care of its owner, coupled with the failure to

REMUNOM
ISSN 2178-6925

Received: 20/04/2026 - **Accepted:** 25/05/2026
Vol: 13.11
DOI: 10.66104/50etnh37
Pages: 1-38

measure parameters such as the urinary protein/creatinine ratio, classifying the animal as a chronic kidney disease patient becomes untenable.

Considering the set of factors such as fluid therapy , appetite stimulant, antiemetic, among other factors that cumulatively contributed to the improvement of biochemical parameters as can be seen in Table 5, between 08/26 and 08/29 it is not possible to attribute the effect to the application of S-PRP, and once again, as in the case of feline 1, its application as an adjunct to the already established and recognized conventional treatment should be questioned, and its use in isolation from other therapies in clinical practice is not recommended.

Case 3 - Feline-3, male, mixed breed, 7 years old. Physical examination (Table 6), laboratory tests (Table 7).

Table 6. Physical Examination - Feline 3

Score	Weight (kg)	Dehydration (%)	TPC (sec)	PAS (mmHg)
3	3.3	7 - 8	2	186

The animal presents with a low body condition score, dehydration, and increased blood pressure .

Source: Authors (2026).

Conduct: Following the anamnesis during a consultation on June 4th at a local clinic, the patient was admitted and received intravenous fluid therapy with Ringer's lactate (50ml/kg/day) and the antiemetic ondansetron (0.5mg/kg) every 8 hours, intravenously. After 48 hours of hospitalization, already hydrated, with no improvement in nausea and no appetite, the patient was discharged and brought home by their caregiver for a single application of S-PRP (February 6th). The patient was then discharged home with a prescription for the antiemetic Cerenia® once a day orally (¼ of a 16mg tablet) for 3 days. Ten days after the application, tests were repeated (February 16th), and an abdominal ultrasound was performed to further assess the case. The results showed improvement in the measured parameters; the patient had an appetite, no episodes of vomiting, and had gained 3.5kg. The tests were repeated again on February 19th and 22nd, with the aim of observing the evolution of the clinical picture as shown in Table 7.

REMUNOM
ISSN 2178-6925

Received: 20/04/2026 - **Accepted:** 25/05/2026
Vol: 13.11
DOI: 10.66104/50etnh37
Pages: 1-38

Table 7. Evaluation of biochemical and hematological parameters of feline 3.

	Pre S-PRP		Post S-PRP		
Parameter	**04/02**	**16/02**	**19/02**	**22/02**	**Reference**
Creatinine (mg/ dL)	14.55	7.91	7.44	5.5	0.5 to 1.7
Urea (mg/ dL)	551.7	259.2	264.0	225.0	20 to 65
Phosphorus (mg/ dL)			13.25		3.29 to 8.28
Hematocrit (%)			21	16	26 to 47
White blood cells /mm3			13,500	12,300	5,500 to 19,500
Platelets / mm3			406,000	232,000	100,000 to 518,000
Proteins (g/ dL)	8.9		8.2	8.6	5.3 to 8.6

Gradual reduction of creatinine after clinical intervention between February 4th and February 22nd.

Source: Authors (2026).

Feline Ultrasound 3 – (February 16, 2026, post-S-PRP application)

Left Kidney: In its usual location, presenting slightly reduced dimensions (3.0 cm). Total loss of the corticomedullary relationship and alteration of the usual morphology and architecture. Parenchyma showing coarse echotexture with focal echogenic and diffuse hyperechoic areas . Absence of renal pelvis dilation. Presence of a lithiasis (calculus) structure in the pelvic recess measuring 0.15 cm. Findings compatible with severe chronic nephropathy (differential diagnoses: congenital malformation/multiple renal infarcts).

Right Kidney: In its usual location, presenting the same structural alterations described in the contralateral kidney: total loss of the corticomedullary relationship , decharacterized morphology and architecture. Diffuse parenchymal echogenicity with more echogenic and hyperechoic areas . Presence of a lithiasis (calculus) structure in the pelvic recess measuring 0.23 cm. Indicative of severe renal nephropathy. As per the report.

The limited data regarding the patient's history and previous examinations, coupled with the short follow-up period, the measurement of few parameters, and the combination of therapies, make it impossible to evaluate the effects of S-PRP in isolation, as well as to accurately classify the patient as having CKD.

REMUNOM
ISSN 2178-6925

Received: 20/04/2026 - **Accepted:** 25/05/2026
Vol: 13.11
DOI: 10.66104/50etnh37
Pages: 1-38

Through analysis of the graphs below (Figures 1 and 2), it is possible to observe a reduction in the biochemical markers of serum creatinine and urea, chosen because they are the most documented parameters in the 3 reported cases; however, these do not show consistency within the sampling interval, as can be seen in the individual descriptions of the figures.

Figure 1 – Comparison of creatinine levels before and after the intervention.

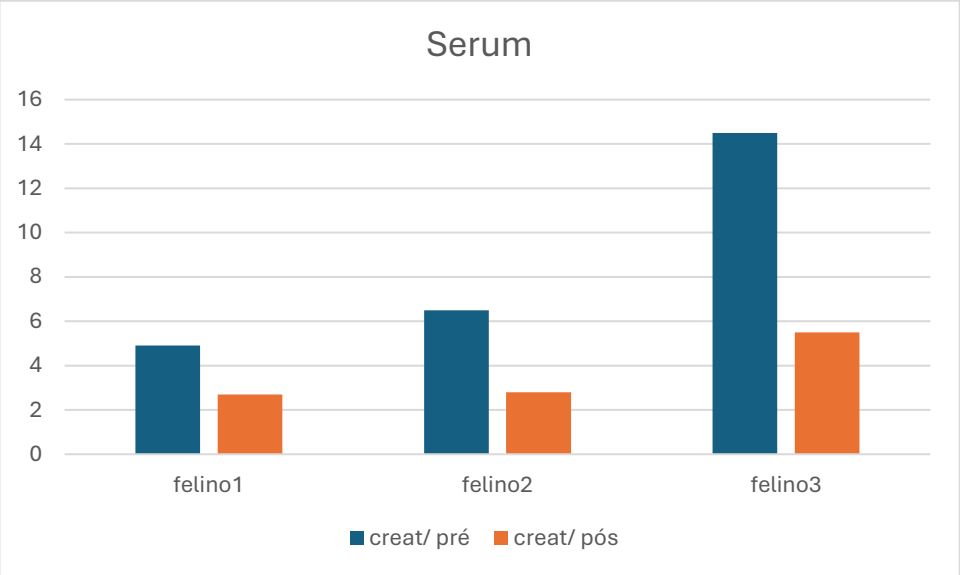

Creatinine measured pre-clinical intervention (blue) and post-clinical intervention (orange). Feline 1, 13-day interval (-45%). Feline 2, 3-day interval (-57%). Feline 3, 18-day interval (-62%).

Source: Authors (2026)

REMUNOM
ISSN 2178-6925

Received: 20/04/2026 - **Accepted:** 25/05/2026
Vol: 13.11
DOI: 10.66104/50etnh37
Pages: 1-38

Figure 2 - Comparison of urea levels before and after the intervention.

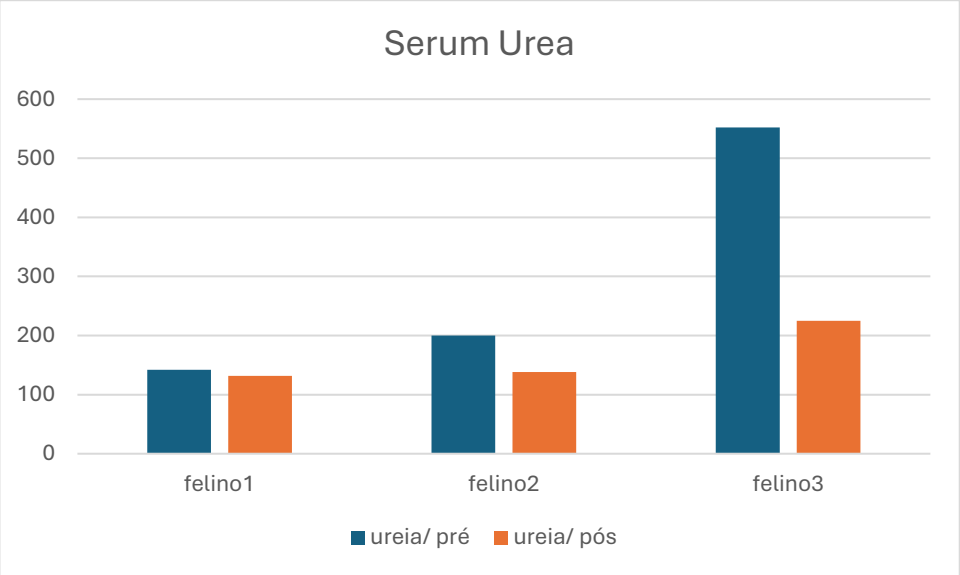

Urea measured before clinical intervention (blue) and after clinical intervention (orange). Feline 1, 13-day interval (-7%). Feline 2, 3-day interval (-31%). Feline 3, 18-day interval (-59%).

Source: Authors (2026).

It is possible to observe a reduction in biochemical markers after clinical management integrating the application of S-PRP concomitantly with conventional therapy. The clinical improvement observed in the reported felines, understood as the maintenance of appetite, reduction of nausea, weight gain, reduction of vomiting episodes, and improved hydration, accompanied by a reduction in biochemical markers, does not have standardized intervals or recurring parameters and therefore should be evaluated with caution.

None of the patients in this report experienced adverse reactions during or after the application of S-PRP during follow-up, which are positive factors that encourage further investigation.

5. Limitations

This study is an exploratory report with significant methodological limitations, such as the absence of a control group, a small number of cases, and the lack of measurement of parameters for patient staging as foreseen by IRIS, 2024. Because it is a retrospective/exploratory clinical case series, there was no rigid temporal standardization of laboratory data collection and a short follow-up period for the

REMUNOM
ISSN 2178-6925

Received: 20/04/2026 - **Accepted:** 25/05/2026
Vol: 13.11
DOI: 10.66104/50etnh37
Pages: 1-38

patients, resulting in the impossibility of attributing the clinical and laboratory results exclusively to S-PRP or accurately measuring the portion of these results resulting from concomitant supportive therapies such as intravenous fluid therapy , antiemetics, and appetite stimulants—therapies that are already well-established.

6. Conclusion

The findings observed in this case series suggest that the systemic use of platelet-rich plasma (S-PRP), associated with conventional treatment, may represent a promising adjuvant approach in felines with clinical and laboratory alterations compatible with renal dysfunction. The absence of adverse effects observed during follow-up reinforces the potential safety of the technique. However, due to the methodological limitations of this study, including the absence of a control group and the heterogeneity of the cases, it is not possible to establish a causal relationship between the application of S-PRP and the observed clinical improvement. Prospective, controlled, and standardized studies are needed to evaluate the efficacy, safety, and ideal protocols for using the technique.

References

ANDERSON, S.; RENNEKE, H. G.; BRENNER, B. M. Therapeutic advantage of converting enzyme inhibitors in arresting progressive renal disease associated with systemic hypertension in rats. *Journal of Clinical Investigation*, v. 77, n. 6, p. 1993-2000, 1986.

BERTOLETTI, Bianca; RAISER, Alceu Gaspar; SCHALEMBERG, Mirian Denise; et al. Protocolos para obtenção de plasma rico em plaquetas (PRP) em gatos: estudo piloto. *Medvep - Revista Científica de Medicina Veterinária - Pequenos Animais e Animais de Estimação*, v. 12, n. 40/41, p. 1-7, 2014.

BROWN, Scott A. et al. Chronic kidney disease in aged cats: clinical features and management. *Veterinary Clinics of North America: Small Animal Practice*, v. 46, n. 6, p. 1015-1032, 2016.

EVANGELISTA, Fernanda Cristina Gontijo. Principais características fisiopatológicas e tratamentos em felinos com doença renal crônica: uma revisão. *Ensaios e Ciências*, v. 27, n. 2, p. 213-221, 2023. DOI: https://doi.org/10.17921/1415-6938.2023v27n2p213-221

REMUNOM
ISSN 2178-6925

Received: 20/04/2026 - **Accepted:** 25/05/2026
Vol: 13.11
DOI: 10.66104/50etnh37
Pages: 1-38

HUNTINGFORD, Janice et al. *The use of platelet rich plasma in the treatment of degenerative joint disease in cats: an exploratory case series*. **Frontiers in Veterinary Science**, v. 11, 2024. DOI: https://doi.org/10.3389/fvets.2024.1394055.

IRIS – INTERNATIONAL RENAL INTEREST SOCIETY. *Guidelines for Chronic Kidney Disease in Cats* . 2024. Available at: https://www.iris-kidney.com . Accessed March 10, 2025.

LANA, José F. S. D.; MORAES, Tomas M. S.; JORGE, Daniel M. F.; FONSECA, Lucas F.; RODRIGUES, Bruno L. *Medicina regenerativa*. Indaiatuba: Brasil Sustentável Editora, 2025.

OLSZEWER, Efrain; ARROYO, Emil; NAKAMURA, Flávia. *PRP: plasma rico em plaquetas*. São Paulo: FAPES Books, 2015.

POLZIN, David J. Chronic kidney disease in small animals. *Veterinary Clinics of North America: Small Animal Practice*, v. 41, n. 1, p. 15-30, 2011.

SPARKES, Andrew H. et al. ISFM consensus guidelines on the diagnosis and management of feline chronic kidney disease. *Journal of Feline Medicine and Surgery*, v. 18, n. 3, p. 219–239, 2016.

VENDRUSCOLO, Carolina P. et al. Uso do plasma rico em plaquetas na medicina veterinária. *Pesquisa Veterinária Brasileira*, v. 38, n. 5, p. 865-875, 2018.