REMUNOM
ISSN 2178-6925

Received: 13/10/2026 - **Accepted:** 17/11/2026
Vol: 13.24
DOI: 10.66104/nd2crn55
Pages: 1-17

SECONDARY PROPHYLACTIC LOAD-BEARING STABILIZATION OF A MECHANICALLY COMPROMISED MANDIBLE AFTER EXTENSIVE POSTOPERATIVE BONE LOSS FOLLOWING THIRD MOLAR EXTRACTION: A 2-YEAR FOLLOW-UP CASE REPORT

ESTABILIZAÇÃO PROFILÁTICA SECUNDÁRIA COM SUPORTE DE CARGA DE UMA MANDÍBULA MECANICAMENTE COMPROMETIDA APÓS PERDA ÓSSEA PÓS-OPERATÓRIA EXTENSA DECORRENTE DE EXODONTIA DE TERCEIRO MOLAR: RELATO DE CASO COM SEGUIMENTO DE 2 ANOS

ESTABILIZACIÓN PROFILÁCTICA SECUNDARIA CON SOPORTE DE CARGA DE UNA MANDÍBULA MECÁNICAMENTE COMPROMETIDA TRAS PÉRDIDA ÓSEA POSOPERATORIA EXTENSA SECUNDARIA A LA EXTRACCIÓN DE UN TERCER MOLAR: INFORME DE UN CASO CON SEGUIMIENTO DE 2 AÑOS

George Douglas Oliveira da Silva
Specialist in Oral Surgery, FAMA Educação, Brazil
E-mail: dr.douglas_oliveira@hotmail.com

Renato de Toledo Breguez
Specialist in Oral Surgery, FAMA Educação, Brazil
E-mail: dr.renatotbreguez@gmail.com

Camila Geovanna Rocha Romero
Graduated in Dentistry, FAMA Educação, Brazil
E-mail: camilaromero59@gmail.com

Izabella Braga de Carvalho Saboia
Graduated in Dentistry, FAMA Educação, Brazil
E-mail: izabella.braga.carvalho@gmail.com

Wagner Humberto Martins dos Santos
M.Sc. in Oral Surgery, Cacoal Regional Hospital, Brazil
E-mail: wagnerhms@gmail.com

CC BY

REMUNOM
ISSN 2178-6925

Received: 13/10/2026 - **Accepted:** 17/11/2026
Vol: 13.24
DOI: 10.66104/nd2crn55
Pages: 1-17

Marcelo Rodrigues Azenha

PhD in Oral Surgery, Ribeirão Preto School of Dentistry (USP), Brazil**,**

E-mail: marceloazenha@yahoo.com.br

Renan de Barros e Lima Bueno

PhD in Oral Surgery, FAMA Educação, Brazil

E-mail: renanbueno@gmail.com

Abstract

Mandibular fracture after third molar extraction is a rare but serious complication associated with postoperative bone loss. Reports of prophylactic fixation usually describe strategies planned prior to extraction of at-risk impacted teeth; stabilization performed after iatrogenic bone loss has occurred remains scarcely documented. We report the case of a 57-year-old woman referred 14 days after a complicated mandibular third molar extraction performed elsewhere, with no preoperative planning records available, presenting extensive bone loss involving the mandibular body and angle, cortical destruction, and high risk of late fracture. Based on clinical and cone-beam computed tomography findings, secondary prophylactic stabilization was performed using a 2.4-mm locking reconstruction plate with bone grafting. The patient was followed for 24 months, with satisfactory functional recovery, preserved mandibular continuity, progressive bone remodeling, and no fracture or fixation-related complications. This case suggests that early stabilization may help prevent late mandibular fracture after substantial postoperative bone loss.

Keywords: Third molar extraction; Mandibular bone loss; Prophylactic stabilization; Reconstruction plate; Internal fixation

Resumo

A fratura mandibular após a exodontia de terceiros molares é uma complicação rara, porém grave, associada à perda óssea pós-operatória. Os relatos de fixação profilática costumam descrever estratégias planejadas antes da extração de dentes impactados de risco; a estabilização realizada após a ocorrência de perda óssea iatrogênica permanece pouco documentada. Relatamos o caso de uma mulher de 57 anos encaminhada 14 dias após uma exodontia complicada de terceiro molar inferior realizada em outro serviço, sem registros de planejamento pré-operatório disponíveis, apresentando perda óssea extensa envolvendo o corpo e o ângulo mandibulares, destruição cortical e alto risco de fratura tardia. Com base nos achados clínicos e na tomografia computadorizada de feixe cônico, foi realizada estabilização profilática secundária com placa de reconstrução com travamento de 2,4 mm e enxerto ósseo. A paciente foi acompanhada por 24 meses, com recuperação funcional satisfatória, continuidade mandibular preservada, remodelação óssea progressiva e ausência de fratura ou de complicações relacionadas à fixação. Este caso sugere que a estabilização precoce pode auxiliar na prevenção de fratura mandibular tardia após perda óssea pós-operatória substancial.

Palavras-chave: Exodontia de terceiro molar; Perda óssea mandibular; Estabilização profilática; Placa de reconstrução; Fixação interna

CC BY

REMUNOM
ISSN 2178-6925

Received: 13/10/2026 - **Accepted:** 17/11/2026
Vol: 13.24
DOI: 10.66104/nd2crn55
Pages: 1-17

Resumen

La fractura mandibular tras la extracción de terceros molares es una complicación poco frecuente, pero grave, asociada a la pérdida ósea posoperatoria. Los informes de fijación profiláctica suelen describir estrategias planificadas antes de la extracción de dientes impactados de riesgo; la estabilización realizada una vez producida la pérdida ósea iatrogénica sigue estando escasamente documentada. Presentamos el caso de una mujer de 57 años remitida 14 días después de una extracción complicada de un tercer molar inferior realizada en otro servicio, sin registros de planificación preoperatoria disponibles, con pérdida ósea extensa que afectaba al cuerpo y al ángulo mandibulares, destrucción cortical y alto riesgo de fractura tardía. Con base en los hallazgos clínicos y en la tomografía computarizada de haz cónico, se realizó una estabilización profiláctica secundaria con una placa de reconstrucción con bloqueo de 2,4 mm e injerto óseo. La paciente fue seguida durante 24 meses, con recuperación funcional satisfactoria, continuidad mandibular preservada, remodelación ósea progresiva y ausencia de fractura o de complicaciones relacionadas con la fijación. Este caso sugiere que la estabilización precoz puede ayudar a prevenir la fractura mandibular tardía tras una pérdida ósea posoperatoria sustancial.

Palabras clave: Extracción de tercer molar; Pérdida ósea mandibular; Estabilización profiláctica; Placa de reconstrucción; Fijación interna

CC BY

REMUNOM
ISSN 2178-6925

Received: 13/08/2026 - **Accepted:** 13/09/2026
Vol:
DOI:
Pages: 1-25

1. Introduction

The extraction of impacted mandibular third molars is one of the most frequently performed procedures in oral and maxillofacial surgery. Although generally considered safe, several complications have been reported, including pain, infection, alveolar osteitis, neurosensory disturbances, and mandibular fracture (Susarla and Dodson, 2004; Blondeau and Daniel, 2007; Bouloux et al., 2007; Azenha et al., 2014).

Mandibular fracture subsequent to third molar extraction is an uncommon complication, with an estimated incidence ranging from 0.0034% to 0.0075% (Libersa et al., 2002). Despite its rarity, this complication may result in significant morbidity and often requires surgical treatment. Risk factors associated with increased susceptibility to fracture include advanced age, male sex, deeply impacted mandibular third molars, extensive osteotomy, infection, pathological bone defects, and reduced residual mandibular bone volume (Chrcanovic and Custodio, 2010; Chrcanovic and Freire-Maia, 2011).

The mandibular angle is the site most commonly affected, as the presence of an impacted third molar and removal of surrounding bone may reduce local biomechanical resistance. Extensive osteotomy during extraction may further decrease mandibular strength and increase the risk of delayed fracture, particularly after resumption of normal masticatory function (Chrcanovic and Custodio, 2010; Chrcanovic and Freire-Maia, 2011; Ethunandan et al., 2012).

Adequate preoperative clinical and radiographic assessment, including cone-beam computed tomography when indicated, is essential to identify patients at increased surgical risk and to guide appropriate treatment planning or referral to an oral and maxillofacial surgeon whenever the anticipated complexity exceeds the operator’s level of training (Susarla and Dodson, 2004; Chrcanovic and Freire-Maia, 2011; Ethunandan et al., 2012). When such assessment or referral is inadequate, complex extractions may result in unanticipated and extensive bone loss, creating a mechanically compromised mandible even in the absence of a completed fracture.

Most reports on mandibular fractures secondary to third molar surgery focus on management after the fracture has occurred (Chrcanovic and Custodio, 2010; Chrcanovic and Freire-Maia, 2011; Ethunandan et al., 2012). Reports describing

CC BY

REMUNOM
ISSN 2178-6925

Received: 13/08/2026 - **Accepted:** 13/09/2026
Vol:
DOI:
Pages: 1-25

prophylactic stabilization are comparatively scarce and, when available, generally describe strategies planned prior to extraction of deeply impacted teeth judged to carry a high fracture risk (Mo et al., 2016). More recent contributions have primarily explored technological approaches — such as customized three-dimensional-printed titanium plates and surgical guides — to prevent intraoperative iatrogenic fracture during the extraction itself (Onica et al., 2025). In contrast, evidence regarding secondary prophylactic stabilization, performed after significant postoperative bone loss has already occurred, remains limited (Ellis and Graham, 2002; Alpert et al., 2003; Wagner et al., 2005).

The present report describes the surgical management and two-year follow-up of a patient treated with secondary prophylactic load-bearing fixation after extensive postoperative mandibular bone loss following a complicated third molar extraction for which no records of preoperative planning were available for review.

2. Case Report

This case report was prepared in accordance with the CARE (CAse REport) guidelines (Riley et al., 2017).

A 57-year-old woman was referred to the outpatient Oral and Maxillofacial Surgery Department 14 days after extraction of the mandibular right third molar performed by another practitioner. She complained of persistent pain in the right retromolar region, lingual and mental nerve paresthesia, and limited mouth opening, with difficulty eating due to pain during mastication. Her medical history was non-contributory. Records of the original procedure, including preoperative radiographs and the surgical report, were not available, as the practitioner who performed the initial extraction did not provide them despite request. The term iatrogenic bone loss is used descriptively in this report; in the absence of preoperative imaging, a pre-existing bone alteration cannot be entirely excluded.

Extraoral examination showed swelling and erythema in the right mandibular angle region, with pain on palpation. Maximum mouth opening was limited to 12 mm, consistent with moderate trismus. Intraoral examination revealed a small amount of purulent and sanguineous discharge from the extraction site following gentle

CC BY

REMUNOM
ISSN 2178-6925

Received: 13/08/2026 - **Accepted:** 13/09/2026
Vol:
DOI:
Pages: 1-25

compression. The patient maintained a stable occlusion, and no signs of mandibular mobility were detected.

A panoramic radiograph obtained at referral showed an extensive radiolucent defect involving the right mandibular angle and posterior body (Figure 1). Cone-beam computed tomography (CBCT) revealed a large osteolytic defect affecting the mandibular angle and posterior body, with severe compromise of the buccal cortical, areas of cortical discontinuity, and marked reduction of residual bone volume. Sequential 1-mm cross-sectional CBCT images demonstrated cortical involvement extending from section 10 to section 15 of the acquired series. Bone sequestra were identified within the defect, with a periosteal reaction along the lateral aspect of the mandible. Axial sections confirmed extensive destruction of the mandibular architecture, with substantial loss of cross-sectional bone support (Figure 2A). Three-dimensional reconstructions demonstrated that the area of bone loss involved a mechanically important region of the mandible, raising substantial concern regarding mechanical stability of the mandibular angle during functional loading (Figures 2B and 2C).

Figure 1. Panoramic radiograph obtained at the initial evaluation showing extensive bone loss involving the right mandibular angle and posterior body after third molar extraction.



Source: Authors' own archive.

CC BY

REMUNOM
ISSN 2178-6925

Received: 13/08/2026 - **Accepted:** 13/09/2026
Vol:
DOI:
Pages: 1-25

Figure 1 shows the panoramic radiograph obtained at the initial evaluation. The reader should note the radiolucent defect involving the right mandibular angle and posterior body, which prompted the request for cone-beam computed tomography.

Figure 2. (A) Cross-sectional CBCT images obtained after mandibular third molar extraction. Axial, panoramic, and sequential cross-sectional reconstructions demonstrate extensive bone loss involving the right mandibular angle, with disruption of cortical bone continuity and marked reduction of residual basal bone support, bone sequestra and periosteal reaction in the right mandible. Three-dimensional CBCT reconstructions of the right mandible. (B) Lateral view and (C) medial view demonstrating the extent of bone loss and cortical destruction in the mandibular angle region. The highlighted mandibular contour illustrates the location of the structurally weakened segment.

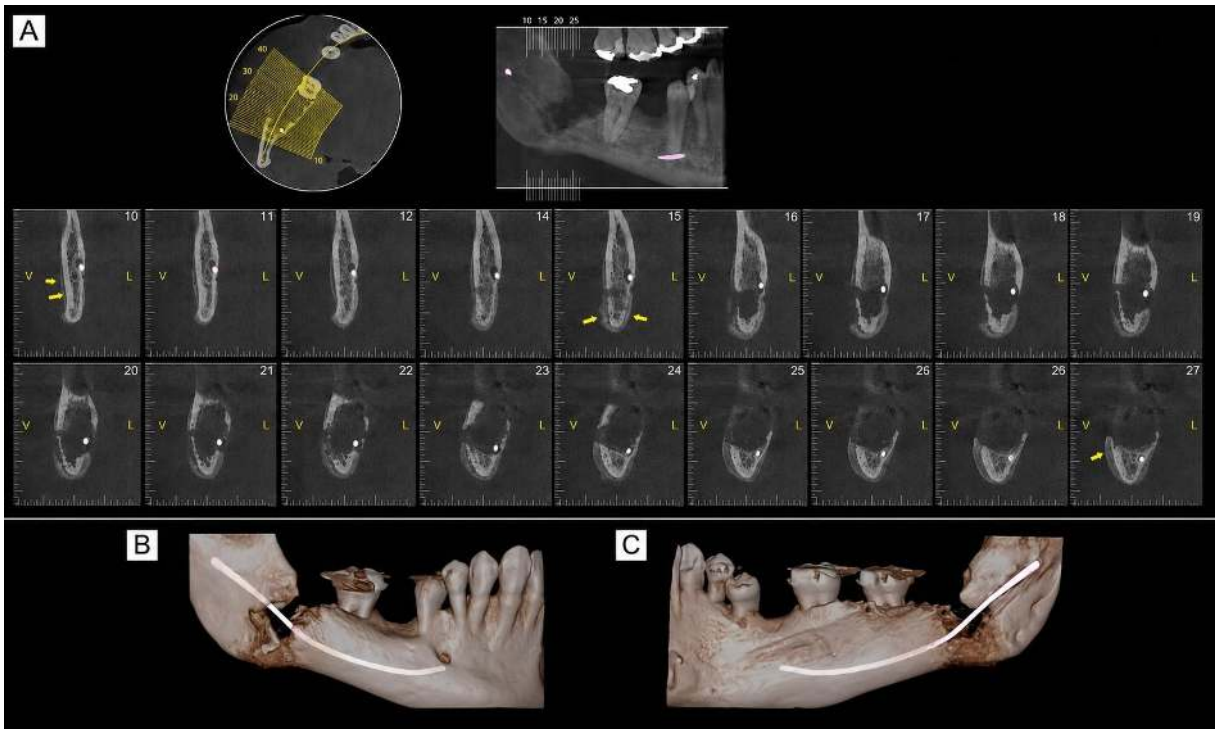

Source: Authors' own archive.

Figure 2 groups the tomographic findings. Panel A presents the sequential cross-sectional slices, in which the yellow arrows mark areas of cortical alteration, and Panels B and C present the three-dimensional reconstructions, where the extent of bone loss at the mandibular angle can be appreciated.

Empirical antibiotic therapy with amoxicillin and metronidazole was prescribed, together with ibuprofen and dipyrone as needed for pain control, and twice-daily rinses with 0.12% chlorhexidine gluconate. A follow-up visit was scheduled after seven days,

CC BY

REMUNOM
ISSN 2178-6925

Received: 13/08/2026 - **Accepted:** 13/09/2026
Vol:
DOI:
Pages: 1-25

and the patient was advised to return immediately if symptoms worsened or fever developed.

At the 7-day follow-up, the patient showed satisfactory clinical improvement, including resolution of pain, reduction of facial swelling, and improvement in mouth opening. Prophylactic stabilization was planned because of the substantial mechanical compromise of the mandibular angle and concern regarding its stability under functional loading. The procedure was performed under general anesthesia through a right submandibular (Risdon) approach. Following exposure of the mandibular body and angle, the extent of the osseous defect was confirmed intraoperatively. Areas of nonviable tissue and bone sequestra were removed, followed by thorough debridement. A 2.4-mm locking reconstruction plate (Traumec, Rio Claro, Brazil) was then adapted along the inferior border of the mandible and secured with bicortical screws placed anterior and posterior to the defect, following load-bearing principles to provide structural support to the weakened segment (Figure 3).

Figure 3. Intraoperative extraoral view obtained through a right submandibular approach showing adaptation and fixation of a 2.4-mm locking reconstruction plate along the inferior border of the mandible.



Source: Authors' own archive.

CC BY

REMUNOM
ISSN 2178-6925

Received: 13/08/2026 - **Accepted:** 13/09/2026
Vol:
DOI:
Pages: 1-25

Figure 3 shows the locking reconstruction plate adapted along the inferior border of the mandible and fixed with screws anterior and posterior to the defect, providing load-bearing support to the weakened segment.

An intraoral approach was subsequently used to access the retromolar region. Granulation tissue was removed and local bone irregularities were smoothed (Figure 4A). The residual defect was grafted with a xenogeneic bone substitute (Bio-Oss®, Geistlich Pharma, Wolhusen, Switzerland) and covered with a resorbable collagen membrane (Bio-Gide®, Geistlich Pharma, Wolhusen, Switzerland) (Figure 4B). The surgical wounds were irrigated and closed in layers, and mandibular stability was confirmed at the end of the procedure.

Figure 4. Intraoperative views of the right mandibular angle. (A) Surgical exposure demonstrating extensive bone loss and marked reduction of residual mandibular support after third molar extraction. (B) Placement of particulate xenogeneic bone graft and collagen membrane within the osseous defect.

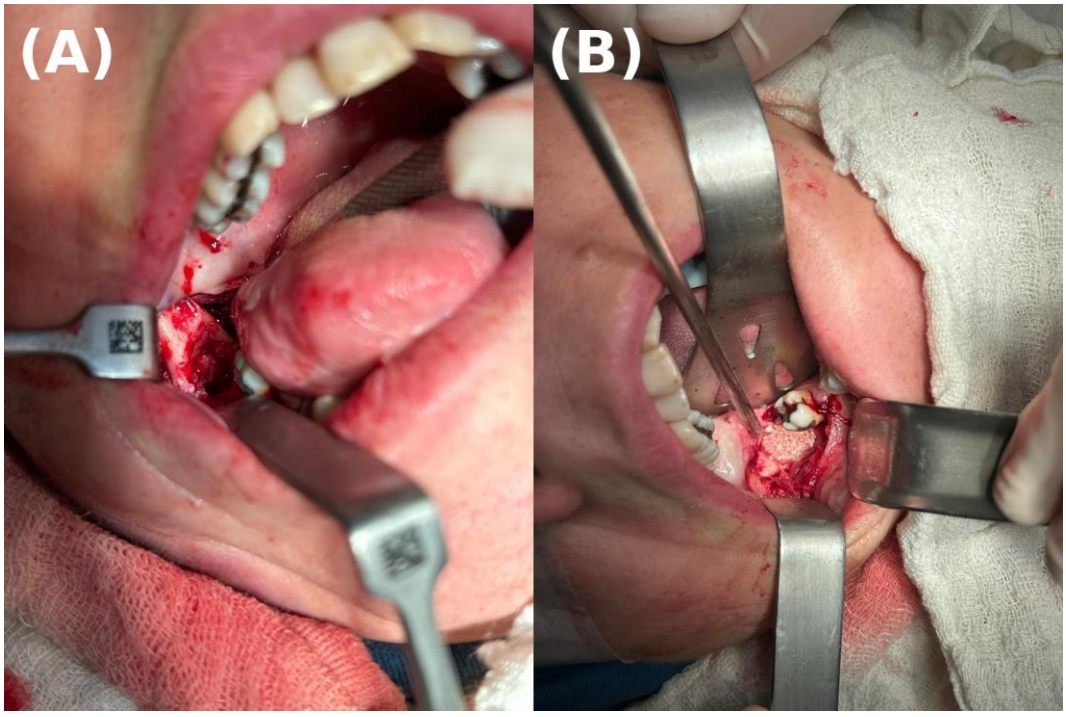

Source: Authors' own archive.

Figure 4 shows the intraoral phase of the procedure. Panel A shows the surgical exposure of the defect, and Panel B shows the placement of the particulate xenogeneic bone graft and the collagen membrane.

CC BY

REMUNOM
ISSN 2178-6925

Received: 13/08/2026 - **Accepted:** 13/09/2026
Vol:
DOI:
Pages: 1-25

The patient was discharged 24 hours after surgery with prescriptions for cephalexin, dexamethasone, ibuprofen, dipyrone as needed, omeprazole, and 0.12% chlorhexidine mouth rinse. At the 7-day follow-up, mild residual swelling and slight limitation of mouth opening were observed, occlusion was stable, and surgical wounds showed satisfactory healing with no signs of infection. Sutures were removed, and follow-up visits were scheduled for 15 and 30 days postoperatively; recovery progressed uneventfully.

At the 2-month follow-up, maximum mouth opening had improved to 50 mm. Lingual and mental nerve paresthesia resolved completely by 3 months postoperatively.

At the 12- and 24-month follow-up, panoramic radiography demonstrated maintenance of mandibular continuity, stable fixation, and progressive bone remodeling in the affected area (Figures 5 and 6), with no evidence of fracture, plate fracture, screw loosening, or recurrent infection. The patient remained asymptomatic, with satisfactory bone remodeling, and did not require additional surgical treatment.

Figure 5. Panoramic radiograph obtained 12 months after surgery showing stable fixation with a 2.4-mm locking reconstruction plate, preservation of mandibular continuity, and progressive bone remodeling in the operated region.



Source: Authors' own archive.

CC BY

REMUNOM
ISSN 2178-6925

Received: 13/08/2026 - **Accepted:** 13/09/2026
Vol:
DOI:
Pages: 1-25

Figure 5 shows the panoramic radiograph obtained 12 months after surgery. The reader should observe the position of the plate and screws, the continuity of the mandibular contour, and the bone remodeling in the operated region.

Figure 6. Panoramic radiograph obtained 24 months after surgery showing stable fixation with a 2.4-mm locking reconstruction plate, preservation of mandibular continuity, and satisfactory bone remodeling in the operated region.

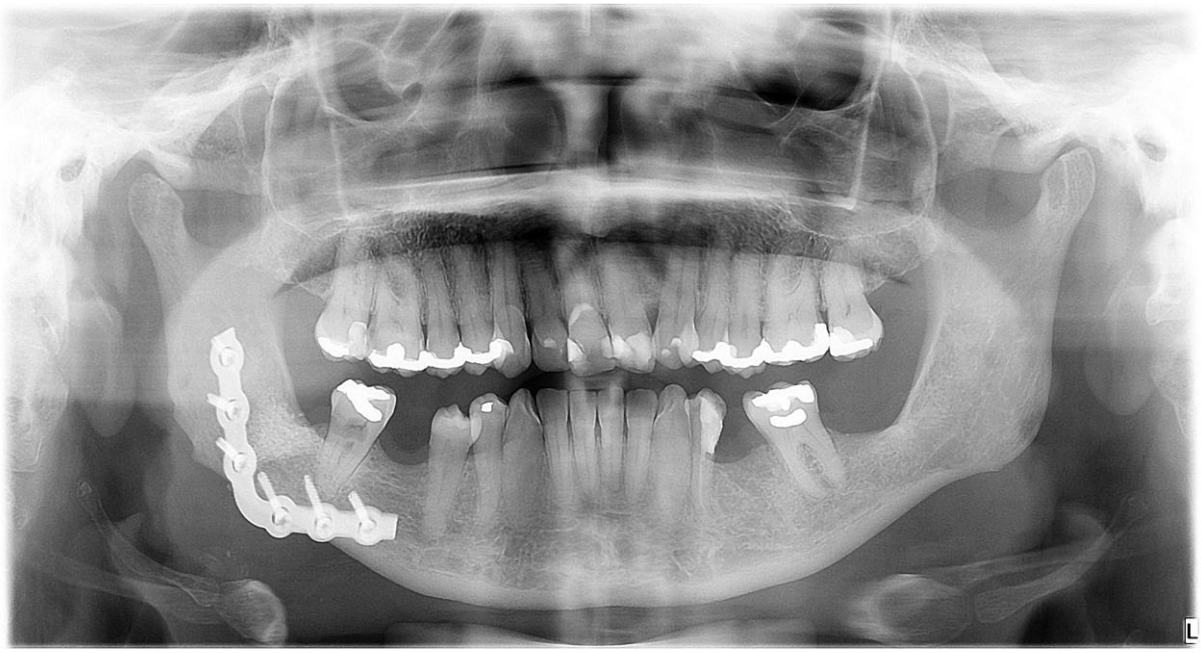

Source: Authors' own archive.

Figure 6 shows the panoramic radiograph obtained 24 months after surgery, which allows direct comparison with Figure 5 and documents stable fixation and continued bone remodeling.

3. Discussion

The present case involved substantial postoperative bone loss following extraction of a mandibular third molar, with marked destruction of the buccal cortical bone and reduction of residual mandibular support. Although no fracture was identified clinically or radiographically, CBCT demonstrated marked structural compromise of the mandibular angle — the region most frequently affected by fractures associated with third molar surgery (Chrcanovic and Custodio, 2010; Chrcanovic and Freire-Maia, 2011; Ethunandan et al., 2012).

CC BY

REMUNOM
ISSN 2178-6925

Received: 13/08/2026 - **Accepted:** 13/09/2026
Vol:
DOI:
Pages: 1-25

Several factors have been associated with mandibular fractures after third molar extraction, including patient age, depth of impaction, extensive osteotomy, tooth position, and reduction of bone volume at the mandibular angle (Chrcanovic and Freire-Maia, 2011; Ethunandan et al., 2012). Chrcanovic and Freire-Maia (2011) emphasized that extensive bone removal during extraction may weaken the mandible and contribute to fracture development postoperatively. Similarly, Ethunandan et al. (2012) reported that most fractures occur after surgery, frequently during normal masticatory activity, when functional forces are reapplied to a previously weakened segment.

Notably, the extensive bone loss observed in the present case was associated with a complex extraction for which no records of preoperative radiographic planning were available for review. This illustrates a broader gap in the literature: careful preoperative clinical and radiographic assessment — including tooth position, depth of impaction, proximity to adjacent structures, and anticipated extent of osteotomy — is essential to identify patients at increased surgical risk and to justify timely referral to an oral and maxillofacial surgeon whenever anticipated complexity exceeds the operator's level of training (Susarla and Dodson, 2004; Chrcanovic and Freire-Maia, 2011; Ethunandan et al., 2012). Early recognition and specialized management of postoperative complications may prevent progression to a completed mandibular fracture requiring more extensive reconstructive surgery (Libersa et al., 2002; Chrcanovic and Freire-Maia, 2011; Ethunandan et al., 2012).

In the present case, tomographic examination demonstrated marked cortical destruction and only a limited amount of residual basal bone, raising concern regarding mechanical stability of the mandibular angle during function. Surgical management was therefore directed not only toward local debridement but also toward reinforcement of mandibular continuity through load-bearing fixation.

Rigid internal fixation is well established for the management of mandibular fractures and defects associated with reduced load-sharing capacity. Reconstruction plates are particularly indicated in situations involving significant bone loss, segmental defects, or compromised mandibular stability (Ellis and Graham, 2002; Alpert et al., 2003). In the present case, a 2.4-mm locking reconstruction plate was selected

CC BY

REMUNOM
ISSN 2178-6925

Received: 13/08/2026 - **Accepted:** 13/09/2026
Vol:
DOI:
Pages: 1-25

because of the extent of bone loss and the limited residual support available at the mandibular angle.

The indication for load-bearing fixation in this patient was not the treatment of an established fracture, but restoration of structural stability in a mandibular segment with markedly reduced residual bone support. A load-sharing approach was considered unlikely to provide sufficient mechanical support given the extent of cortical destruction and the limited residual bone stock available for screw purchase; a load-bearing reconstruction plate was therefore selected to support the weakened segment during bone healing and remodeling.

Most reports in the literature describe treatment after fracture occurrence (Chrcanovic and Custodio, 2010; Chrcanovic and Freire-Maia, 2011; Ethunandan et al., 2012). Prophylactic fixation in the context of third molar surgery has been described almost exclusively as a strategy planned concomitantly with or prior to extraction: either prior to extraction of deeply impacted teeth judged to carry a high fracture risk (Mo et al., 2016), or, more recently, concomitantly with extraction in edentulous, severely atrophic mandibles with chronic dental infection, again in anticipation of extraction-related fracture risk in an already fragile mandible (Brito et al., 2026). We describe the present approach as “secondary” prophylactic fixation to distinguish it from these strategies: in our patient, stabilization was performed only after the extraction had already been carried out elsewhere and had already resulted in extensive bone loss, rather than concomitantly with or in anticipation of a still-unperformed extraction. To our knowledge, this scenario — reinforcement of a mandible already compromised by a completed surgical event, before a clinically established fracture develops — remains infrequently reported, particularly with a follow-up period as long as 24 months. Recent literature has otherwise focused on preventing intraoperative iatrogenic fracture during the extraction itself, such as customized three-dimensional-printed titanium plates and surgical guides (Onica et al., 2025), which addresses a different stage of risk than the one described here.

Clinical and radiographic follow-up demonstrated satisfactory healing after 24 months, with no signs of infection, hardware failure, occlusal alteration, or fracture.

CC BY

REMUNOM
ISSN 2178-6925

Received: 13/08/2026 - **Accepted:** 13/09/2026
Vol:
DOI:
Pages: 1-25

These findings suggest that secondary prophylactic load-bearing stabilization may represent a treatment option in selected patients presenting with substantial mandibular bone loss identified after third molar extraction, particularly when cortical destruction and reduced residual bone volume raise concern about mechanical stability during function. In practice, this supports obtaining CBCT imaging whenever postoperative bone loss appears extensive on panoramic radiography, and considering early prophylactic stabilization — rather than awaiting clinical or radiographic signs of an established fracture — before resumption of normal masticatory loading. As with any single case report, a preventive effect on fracture occurrence cannot be established, since it cannot be known whether this patient would have progressed to a completed fracture in the absence of surgical intervention.

4. Conclusion

Secondary prophylactic load-bearing fixation associated with bone grafting provided adequate stabilization of a severely weakened mandible following extensive postoperative bone loss after third molar extraction. Mandibular continuity was preserved, satisfactory healing was achieved, and no fracture or fixation-related complications were observed during the 24-month follow-up period.

Declarations

Funding. This research did not receive any specific grant from funding agencies in the public, commercial, or not-for-profit sectors.

Competing interests. The authors declare that they have no financial or non-financial interests to disclose that are relevant to the content of this article.

Ethics approval. The study was performed in accordance with the ethical principles of the Declaration of Helsinki and its later amendments.

Consent to participate. Informed consent to participate was obtained from the patient.

Clinical trial number. Not applicable.

CC BY

REMUNOM
ISSN 2178-6925

Received: 13/08/2026 - **Accepted:** 13/09/2026
Vol:
DOI:
Pages: 1-25

Consent to publish. The authors affirm that the patient provided written informed consent for publication of this case report and the accompanying clinical images (Figures 1–6).

Data availability. The data supporting the findings of this case report (clinical and imaging data) are included within the article. No additional datasets were generated or analysed.

Declaration of generative AI and AI-assisted technologies in the manuscript preparation process. During the preparation of this work the author(s) used Claude (Anthropic) in order to assist with language refinement, grammar correction, and improvement of readability. After using this tool, the author(s) reviewed and edited the content as needed and take(s) full responsibility for the content of the published article. No artificial intelligence tool was used to generate, interpret, or analyze clinical data, nor to draw scientific conclusions.

References

Alpert, B., et al. “New Innovations in Craniomaxillofacial Fixation: The Locking Plate Concept.” *International Journal of Oral and Maxillofacial Surgery*, vol. 32, 2003, pp. 693-96.

Azenha, M. R., et al. “Accidents and Complications Associated with Third Molar Surgeries Performed by Dentistry Students.” *Oral and Maxillofacial Surgery*, vol. 18, 2014, pp. 459-64, https://doi.org/10.1007/s10006-013-0439-9.

Blondeau, F., and N. G. Daniel. “Extraction of Impacted Mandibular Third Molars: Postoperative Complications and Their Risk Factors.” *Journal of the Canadian Dental Association*, vol. 73, 2007, p. 325.

Bouloux, G. F., et al. “Complications of Third Molar Surgery.” *Oral and Maxillofacial Surgery Clinics of North America*, vol. 19, 2007, pp. 117-28, https://doi.org/10.1016/j.coms.2006.11.013.

CC BY

REMUNOM
ISSN 2178-6925

Received: 13/08/2026 - **Accepted:** 13/09/2026
Vol:
DOI:
Pages: 1-25

Brito, G. C., et al. “Atrophic Jaws with Infected Third Molars: The Role of Prophylactic Internal Fixation.” *Journal of Craniofacial Surgery*, vol. 37, no. 6, 2026, pp. e523-e526, https://doi.org/10.1097/SCS.0000000000012221.

Chrcanovic, B. R., and A. L. N. Custodio. “Considerations of Mandibular Angle Fractures During and After Surgery for Removal of Third Molars: A Review of the Literature.” *Oral and Maxillofacial Surgery*, vol. 14, 2010, pp. 71-80.

Chrcanovic, B. R., and B. Freire-Maia. “Considerations of Mandibular Angle Fractures Associated with Impacted Lower Third Molars.” *Oral and Maxillofacial Surgery*, vol. 15, 2011, pp. 203-08.

Ellis, E., III, and J. Graham. “Use of a 2.4-mm Locking Reconstruction Plate for Mandibular Continuity Defects.” *Journal of Oral and Maxillofacial Surgery*, vol. 60, 2002, pp. 795-801.

Ethunandan, M., et al. “Iatrogenic Mandibular Fractures Following Removal of Impacted Third Molars: An Analysis of 130 Cases.” *British Dental Journal*, vol. 212, 2012, pp. 179-84.

Libersa, P., et al. “Immediate and Late Mandibular Fractures After Third Molar Removal.” *Journal of Oral and Maxillofacial Surgery*, vol. 60, 2002, pp. 163-65.

Mo, Y., et al. “Prevention of Iatrogenic Mandibular Fracture Associated with Deeply Impacted Tooth Removal – Report of Two Borderline Cases.” *Journal of Dental and Oral Disorders*, vol. 2, 2016, article 1048.

Onica, C. A., et al. “Customized Titanium Plates for Preventing Mandibular Fractures in Lower Third Molar Extractions.” *Journal of Functional Biomaterials*, vol. 16, 2025, article 64, https://doi.org/10.3390/jfb16020064.

CC BY

REMUNOM
ISSN 2178-6925

Received: 13/08/2026 - **Accepted:** 13/09/2026
Vol:
DOI:
Pages: 1-25

Riley, D. S., et al. “CARE Guidelines for Case Reports: Explanation and Elaboration Document.” *Journal of Clinical Epidemiology*, vol. 89, 2017, pp. 218-35, https://doi.org/10.1016/j.jclinepi.2017.04.026.

Susarla, S. M., and T. B. Dodson. “Risk Factors for Third Molar Extraction Difficulty.” *Journal of Oral and Maxillofacial Surgery*, vol. 62, 2004, pp. 1363-71, https://doi.org/10.1016/j.joms.2004.05.214.

Wagner, K. W., et al. “Pathological Mandibular Fractures Following Third Molar Removal.” *International Journal of Oral and Maxillofacial Surgery*, vol. 34, 2005, pp. 722-26, https://doi.org/10.1016/j.ijom.2005.03.003.

CC BY