REMUNOM
ISSN 2178-6925

Received: 19/10/2026 - **Accepted:** 20/11/2026
Vol: 13.24
DOI: 10.66104/acsqf297
Pages: 1-19

CARACTERIZAÇÃO ANATÔMICA DO FORAME MENTUAL EM MANDÍBULAS SECAS

ANATOMICAL CHARACTERIZATION OF THE MENTAL FORAMEN IN DRY JAWS

CARACTERIZACIÓN ANATÓMICA DEL FORAMEN MENTONIANO EN MANDÍBULAS SECAS

Luyra Elykia Daniel dos Santos[1]; Cristina Freitas de Sousa[1]; Arthur Felipe de Brito Andrade[2]; Arthur Willian de Lima Brasil[3]; Ilan Hudson Gomes de Santana*[4]; Ana Karine Farias da Trindade[3]; Eliane Marques Duarte de Sousa[3]; Luciana Sousa Jacks[3]; Monique Danyelle Emiliano Batista Paiva[3]

[1] Graduate in Dentistry from the Federal University of Paraíba, Brazil.

[2] Graduate Program in Oral Biology, School of Dentistry, University of Campinas, Piracicaba, São Paulo, Brazil.

[3] Professor in the Department of Morphology at the Federal University of Paraíba, Brazil.

[4] Undergraduate in Dentistry at the Federal University of Paraíba, Brazil.

* Corresponding author: Ilan Hudson Gomes de Santana. E-mail: ilan.hudson@academico.ufpb.br

Resumo

Objetivo: Caracterizar o forame mentual (FM) quanto à posição, orientação e relações morfométricas em mandíbulas dentadas e edêntulas. Materiais e Métodos: Este estudo observacional analisou 29 mandíbulas humanas secas (14 dentadas e 15 edêntulas), classificadas segundo condição dentária e sexo. A posição do FM foi determinada pela classificação de Tebo e Telford, e a orientação foi definida pelo seu maior eixo. Medidas lineares em relação a marcos anatômicos mandibulares foram obtidas com paquímetro digital. A concordância entre examinadores foi avaliada pelo teste Kappa, e as análises estatísticas incluíram testes t pareado e independente ($p < 0,05$). Resultados: Todas as mandíbulas apresentaram FM bilateral. A posição mais frequente foi abaixo do segundo pré-molar mandibular (direita: 71,42%; esquerda: 64,28%), seguida da posição entre os pré-molares. Nas mandíbulas dentadas, predominou a orientação oblíqua descendente (direita: 92,85%; esquerda: 85,71%). Nas mandíbulas edêntulas, a orientação horizontal foi mais frequente à direita (53,33%), enquanto a orientação oblíqua descendente predominou à esquerda (60%). As mandíbulas dentadas apresentaram medidas significativamente maiores, especialmente nas distâncias entre o FM e a crista alveolar e entre a margem inferior do corpo mandibular e a crista alveolar ($p < 0,0001$). Conclusão: O FM localiza-se mais frequentemente abaixo do segundo pré-molar mandibular e apresenta predominantemente orientação oblíqua descendente. O edentulismo altera significativamente sua posição em decorrência da reabsorção óssea alveolar, reforçando a importância do conhecimento anatômico preciso para procedimentos clínicos seguros.

Palavras-chave: Forame mentual; Mandíbula; Anatomia.

CC BY

REMUNOM
ISSN 2178-6925

Received: 19/10/2026 - **Accepted:** 20/11/2026
Vol: 13.24
DOI: 10.66104/acsqf297
Pages: 1-19

Abstract

Objective: To characterize the mental foramen (MF) regarding its position, orientation, and morphometric relationships in dentate and edentulous mandibles. Materials and Methods: This observational study analyzed 29 dry human mandibles (14 dentate, 15 edentulous). Specimens were classified by dentition status and sex. The MF position was determined using the Tebo and Telford classification, and orientation was defined by its major axis. Linear measurements to mandibular landmarks were obtained with a digital caliper. Examiner agreement was assessed (Kappa), and statistical analyses included paired and independent t-tests ($p < 0.05$). Results: All mandibles presented bilateral MF. The most frequent position was below the second mandibular premolar (right: 71.42%; left: 64.28%), followed by a location between premolars. In dentate mandibles, the predominant orientation was oblique descending (right: 92.85%; left: 85.71%). In edentulous mandibles, a horizontal orientation was more frequent on the right (53.33%), while oblique descending predominated on the left (60%). Dentate mandibles showed significantly greater measurements, especially for MF-AC and IMB-AC ($p < 0.0001$). Conclusion: The MF is most commonly located below the second premolar and shows a predominantly oblique descending orientation. Edentulism significantly alters its position due to alveolar bone resorption, highlighting the importance of precise anatomical knowledge for safe clinical procedures.

Keywords: Mental foramen; Mandible; Anatomy.

Resumen

Objetivo: Caracterizar el foramen mentoniano (FM) en cuanto a su posición, orientación y relaciones morfométricas en mandíbulas dentadas y edéntulas. Materiales y Métodos: Este estudio observacional analizó 29 mandíbulas humanas secas (14 dentadas y 15 edéntulas), clasificadas según el estado dentario y el sexo. La posición del FM se determinó mediante la clasificación de Tebo y Telford, y la orientación se definió por su eje mayor. Las mediciones lineales con respecto a puntos anatómicos mandibulares se obtuvieron con un calibrador digital. La concordancia entre examinadores se evaluó mediante Kappa y los análisis estadísticos incluyeron pruebas t pareadas e independientes ($p < 0,05$). Resultados: Todas las mandíbulas presentaron FM bilateral. La posición más frecuente fue debajo del segundo premolar mandibular (derecha: 71,42%; izquierda: 64,28%), seguida de la posición entre los premolares. En las mandíbulas dentadas predominó la orientación oblicua descendente (derecha: 92,85%; izquierda: 85,71%). En las mandíbulas edéntulas, la orientación horizontal fue más frecuente a la derecha (53,33%), mientras que la orientación oblicua descendente predominó a la izquierda (60%). Las mandíbulas dentadas presentaron medidas significativamente mayores, especialmente en las distancias entre el FM y la cresta alveolar y entre el margen inferior del cuerpo mandibular y la cresta alveolar ($p < 0,0001$). Conclusión: El FM se localiza con mayor frecuencia debajo del segundo premolar mandibular y presenta predominantemente una orientación oblicua descendente. El edentulismo altera significativamente su posición debido a la reabsorción ósea alveolar, destacando la importancia del conocimiento anatómico preciso para procedimientos clínicos seguros.

Palabras clave: Foramen mentoniano; Mandíbula; Anatomía.

1. Introduction

The mandible is part of the viscerocranium, which is located around the cephalic components of the respiratory and digestive systems (Bruna-Mejias *et al.*). It is a single bone located in the lower third of the face and is the only mobile bone of the skull (Tiwari)

CC BY

REMUNOM
ISSN 2178-6925
Received: 19/10/2026 - **Accepted:** 20/11/2026
Vol: 13.24
DOI: 10.66104/acsqf297
Pages: 1-19

On the internal surface of the mandibular body lies the mandibular canal, a curved canal that runs obliquely throughout the body, beginning its path at the mandibular foramen and exiting through the mental foramen (MF) (De Silva and Perera)

An oral region of significant concern during periapical surgery is that of the lower premolars, due to the proximity to the mental nerve. The best way to avoid damage to this structure is to be aware of its exact location (Mohebiniya and Kamani). This knowledge is highly relevant in dental practice, both for effective anesthesia and for surgical incisions that avoid injury to the mental neurovascular bundle, thereby preventing paresthesia (Goyushov *et al.*; Mallahi *et al.*).

This understanding is also essential for accurate diagnosis in radiographs, with periapical images being the most commonly used in dental offices. In this context, professionals must master the identification of anatomical structures that may mimic pathological conditions (Liu *et al.*). The MF can be observed as a circular radiolucent area at the level of or below the roots of the lower premolars.

Physiological changes resulting from tooth loss and aging, along with the weakening of the masticatory system, lead to structural changes in the mandible, causing a resorption process due to the lack of mechanical stimulus. Consequently, the MF may be located closer to, or even on, the residual ridge a fact that should also be considered (Amaan *et al.*).

During routine procedures, such as anesthesia, and more complex ones, such as orthognathic surgeries, the neurovascular bundle emerging through the MF can be damaged, resulting in temporary or permanent injuries. Thus, locating the MF is crucial before any procedure in this region (Habash *et al.*).

This research aims to gather information regarding the position of the MF so that dental professionals can perform clinical and surgical procedures more safely, given that the foramen is neither visible nor palpable.

2. Methodology

The sample consisted of dry mandibles from the Ossuary collection of the Department of Morphology at the Federal University of Paraíba, Campus I, João

CC BY

REMUNOM
ISSN 2178-6925
Received: 19/10/2026 - **Accepted:** 20/11/2026
Vol: 13.24
DOI: 10.66104/acsqf297
Pages: 1-19

Pessoa, PB, Brazil. Adult mandibles without signs of bone degradation in the area to be studied, of both sexes, dentate and edentulous, were included. Mandibles with destroyed or damaged anatomical landmarks required for measurement were excluded. Data collection was performed by two previously calibrated examiners. The Kappa test was applied to analyze intra- and inter-examiner agreement.

2.1 Characterization of the mandibles

After selecting the mandibles according to the inclusion and exclusion criteria, they were divided into two groups: Group 1 – dentate mandibles (n = 14); Group 2 – edentulous mandibles (n = 15).

A mandible was considered dentate if it contained dental elements or preserved alveolar processes, and edentulous if there was no evidence of dental elements or alveolar processes. The mandibles in both groups were cataloged as female or male through quantitative analysis using a digital caliper, a flexible millimeter ruler, and a protractor.

The following measurements were performed based on parameters described in the literature: Bigonial distance (GG) – female: 84.62 to 86.60 mm; male: 89.92 to 92.53 mm; Bicondylar distance of the mandible (DBMC) – female: 114.36 to 117.20 mm; male: 119.92 to 122.34 mm; Mandibular angle – approximately 124.4° for females and 127.6° for males, according to the Galvão e Silva technique as described by Vanrell (2019); and Body height of the mandible – female: 27.0 to 31.0 mm; male: 33.5 to 41.0 mm (Arthanari *et al.*). Figure 1 illustrates the measurements performed to determine the sex of the mandibles.

CC BY

REMUNOM
ISSN 2178-6925
Received: 19/10/2026 - **Accepted:** 20/11/2026
Vol: 13.24
DOI: 10.66104/acsqf297
Pages: 1-19

Figure 1. Measurements for sex determination. Bigonial distance (A), bicondylar distance (B), mandibular angle (C and D), and height of the mandibular body (E).

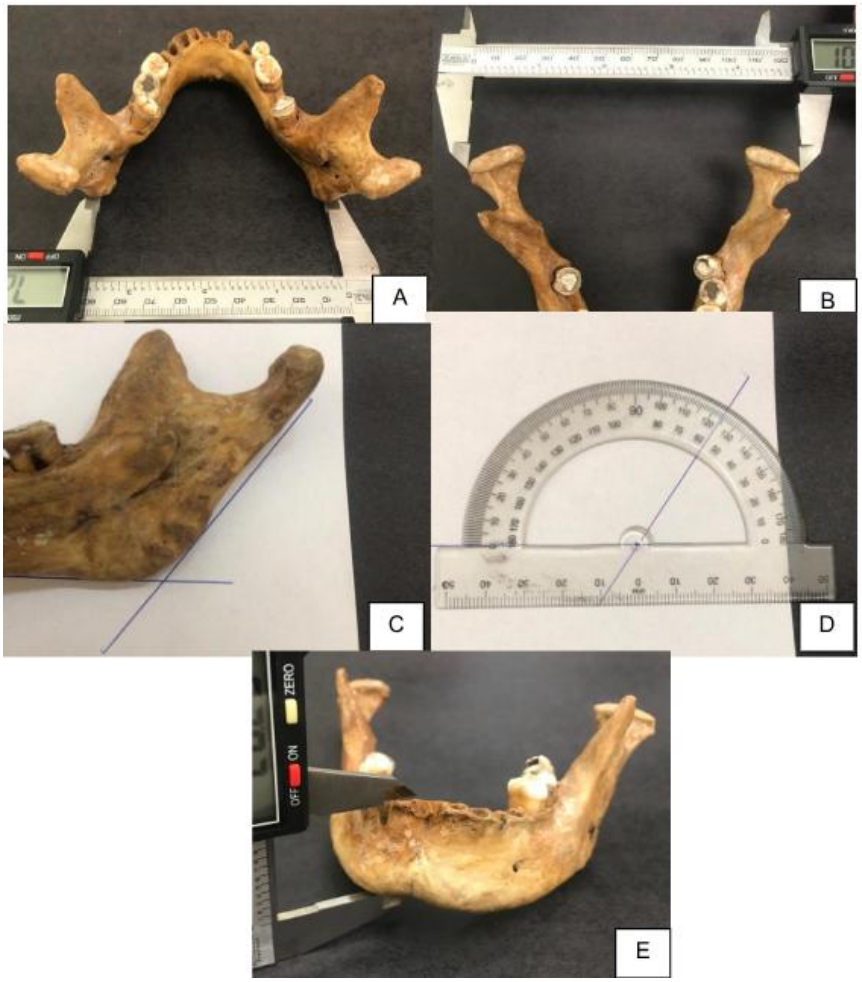

Source: Research. DMORF/CCS/UFPB Collection.

Subsequently, the mandibles were divided into four groups: Group A – composed of dentate male mandibles (n = 12); Group B – composed of edentulous male mandibles (n = 11); Group C – composed of dentate female mandibles (n = 2); and Group D – composed of edentulous female mandibles (n = 4).

2.2 Morphological and morphometric analysis of the mental foramen

After completing the cataloging process according to dentate or edentulous condition and sex, analyses and measurements of each mandible were performed using a digital caliper and a flexible millimeter ruler.

The position of the mental foramen in relation to the dental elements was assessed and classified according to the method proposed by Tebo and Telford

CC BY

REMUNOM
ISSN 2178-6925
Received: 19/10/2026 - **Accepted:** 20/11/2026
Vol: 13.24
DOI: 10.66104/acsqf297
Pages: 1-19

(Bosykh *et al.*): I – below the mandibular canine; II – below the first mandibular premolar; III – between the mandibular premolars; IV – below the second mandibular premolar; and V – below the first mandibular molar.

For this assessment, the methodology involved determining two parallel vertical imaginary lines passing through the anterior and posterior margins of the mental foramen. The tooth located predominantly within the space between these two lines was identified, as illustrated in Figure 2.

Figure 2. Definition of the position of the mental foramen (MF) in relation to the dental elements. In this example, the foramen is associated with the second mandibular premolar.



Source: Research. DMORF/CCS/UFPB Collection.

Linear vertical and horizontal measurements of the mental foramen to anatomical landmarks, as well as between anatomical landmarks, were performed on both sides of each mandible and categorized as follows: (MF-SM) – distance from the mental foramen to the mandibular symphysis; (MF-PBR) – distance from the mental foramen to the posterior border of the mandibular ramus; (MF-IMB) – distance from the mental foramen to the inferior margin of the mandibular body; (MF-AC) – distance from the mental foramen to the alveolar crest; (IMB-AC) – distance from the inferior margin of the mandibular body to the alveolar crest; (SM-PBR) – distance from the mandibular symphysis to the posterior border of the mandibular ramus; and (MF-MF) – distance between the right and left mental foramina. Figure 3 illustrates the process in detail

CC BY

REMUNOM
ISSN 2178-6925
Received: 19/10/2026 - **Accepted:** 20/11/2026
Vol: 13.24
DOI: 10.66104/acsqf297
Pages: 1-19

Figure 3. Linear vertical and horizontal measurements. MF-SM: distance from the mental foramen to the mandibular symphysis (A); MF-PBR: distance from the mental foramen to the posterior border of the mandibular ramus (B); MF-IMB: distance from the mental foramen to the inferior margin of the mandibular body (C); MF-AC: distance from the mental foramen to the alveolar crest (D); IMB-AC: distance from the inferior margin of the mandibular body to the alveolar crest (E); SM-PBR: distance from the mandibular symphysis to the posterior border of the mandibular ramus (F); MF-MF: distance between the right and left mental foramina (G).

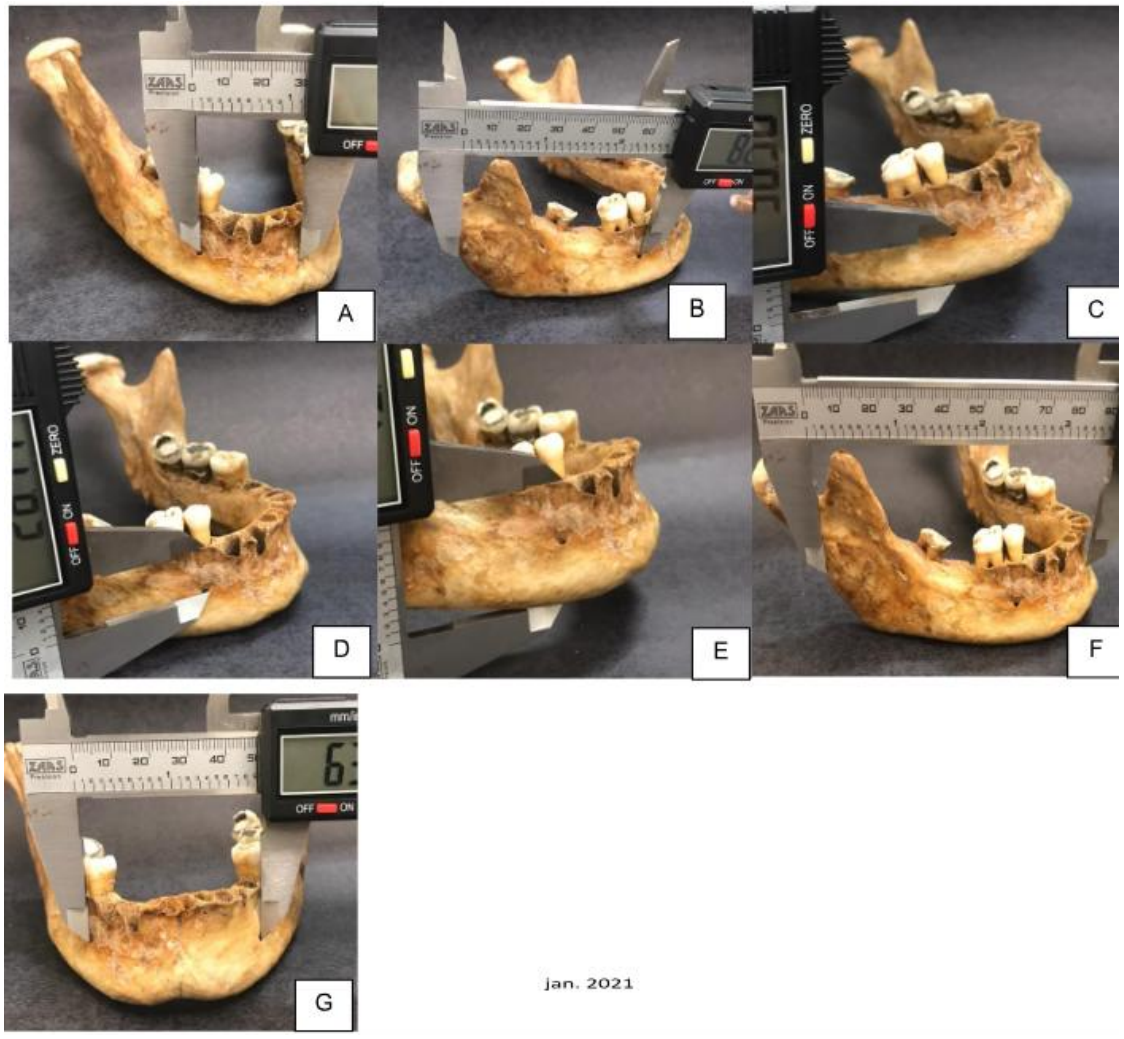

Source: Research. DMORF/CCS/UFPB Collection.

To characterize the orientation of the mental foramen, the classification proposed by Lima (Zmyslowska-Polakowska *et al.*) was applied, which defines the orientation

CC BY

REMUNOM
ISSN 2178-6925
Received: 19/10/2026 - **Accepted:** 20/11/2026
Vol: 13.24
DOI: 10.66104/acsqf297
Pages: 1-19

of the foramen according to its greatest diameter: H – Horizontal; V – Vertical; OA – Oblique Ascending; OD – Oblique Descending, as shown in figure 4:

Figure 4. Characterization of the orientation of the mental foramen. Vertical (V), Horizontal (H), and Oblique Descending (OD).



Source: Research. DMORF/CCS/UFPB Collection.

3. Results

The sample of the present study comprised 29 mandibles, distributed as follows: dentate mandibles (n = 14), of which 2 were female and 12 male, and edentulous mandibles (n = 15), of which 4 were female and 11 male.

The number of male specimens (n = 23) was greater than that of female specimens (n = 6). Therefore, the number of female samples was insufficient to provide a reliable approximation or representative estimate for this variable. A Chi-square goodness-of-fit test was performed to assess the homogeneity between sexes, revealing that the distribution of dentate mandibles was not uniform (p = 0.008). Consequently, no statistical analysis was conducted to compare the distance of the mental foramen to mandibular anatomical landmarks between genders, as initially intended in the study objectives.

Non-parametric data were evaluated using the Kappa test, which showed a very strong agreement between the two examiners (K = 0.837; p = 0.001). Parametric data were analyzed using the independent samples T-test (T = -0.20), also demonstrating good concordance between examiners, with no statistically significant difference (p = 0.984). This confirms that both examiners were well-calibrated, with consistent measurement results.

CC BY

REMUNOM
ISSN 2178-6925
Received: 19/10/2026 - **Accepted:** 20/11/2026
Vol: 13.24
DOI: 10.66104/acsqf297
Pages: 1-19

Among the 29 mandibles analyzed, all presented mental foramina bilaterally (on both right and left sides).

Within the dentate mandible group, the position of the mental foramen relative to the dental elements was assessed. The most prevalent position was below the second mandibular premolar, both on the right side (71.42%) and the left side (64.28%). The second most common position was between the mandibular premolars, with 28.57% on the right side and 35.71% on the left side. Specifically, on the right side, among the 14 mandibles analyzed, 10 specimens (71.42%) had the mental foramen located below the second premolar, while 4 specimens (28.57%) had it positioned between the premolars. On the left side, 9 specimens (64.28%) had the foramen below the second premolar, and 5 specimens (35.71%) presented it between the premolars, as shown in Table 1. No statistically significant difference was observed between the two most prevalent positions on the same side when applying the Chi-square goodness-of-fit test.

Table 1. Position of the mental foramen in relation to dental elements. João Pessoa, 2025.

Side	Below the 2nd mandibular premolar	Between the mandibular premolars	p
R	10	4	0.18(1)
L	9	5	0.42(1)

2nd MP: Second mandibular premolar; MPs: Mandibular premolars; R: Right side; L: Left side. p: Level of statistical significance. (1): Based on the Chi-square goodness-of-fit test.

Source: Research, 2025

The results of the evaluation of the orientation of the major axis of the mental foramen (MF) opening indicated that most MFs in the dentate mandible group exhibited an oblique descending orientation, both on the right side (92.85%) and the left side (85.71%), meaning the foramen opening is directed from superior to inferior and posterior to anterior. No ascending oblique orientation was recorded.

In the edentulous mandible group, on the right side, the major axis was horizontal (53.33%), followed by oblique descending (40%), while on the left side, it was oblique descending (60%), followed by horizontal (26.66%). Similarly, no ascending oblique orientations were observed (Table 2).

CC BY

REMUNOM
ISSN 2178-6925
Received: 19/10/2026 - **Accepted:** 20/11/2026
Vol: 13.24
DOI: 10.66104/acsqf297
Pages: 1-19

Table 2. Orientation of the mental foramen in dentate and edentulous mandibles. João Pessoa, 2025.

	Dentate	Dentate	Edentulous	Edentulous
	R	L	R	L
H	0	1	8	4
V	1	1	1	2
OA	0	0	0	0
OD	13	12	6	9

Source: Research.

H: Horizontal; V: Vertical; OA: Ascending oblique; OD: Descending oblique; R: Right side; L: Left side.

The measurements of the vertical and horizontal linear distances from the mental foramen to anatomical landmarks and between anatomical points, on both sides of each mandible, can be observed in Table 3.

CC BY

REMUNOM
ISSN 2178-6925

Received: 19/10/2026 - **Accepted:** 20/11/2026
Vol: 13.24
DOI: 10.66104/acsqf297
Pages: 1-19

Table 3. Comparison of variables in dentate and edentulous mandibles. João Pessoa, 2025.

Distance	Side	Dentate Mean (SD), mm	Within dentate p[1]	Edentulous Mean (SD), mm	Within edentulous p[1]	Between groups p[2]
FM-SM	R	25.57 (2.36)	0.91	23.45 (2.32)	0.06	**0.02***
FM-SM	L	25.60 (2.45)	0.91	24.06 (2.20)	0.06	0.08
FM-MPR	R	70.71 (5.47)	**0.004***	65.86 (4.96)	0.13	**0.01***
FM-MPR	L	69.41 (5.57)	**0.004***	64.87 (5.41)	0.13	**0.03***
FM-MICM	R	14.39 (1.86)	0.09	12.75 (2.12)	0.30	**0.03***
FM-MICM	L	13.96 (1.81)	0.09	13.06 (2.00)	0.30	0.21
FM-MA	R	13.07 (2.55)	0.30	6.97 (4.12)	0.65	**<0.0001***
FM-MA	L	12.57 (2.55)	0.30	6.67(3.35)	0.65	**<0.0001***
MICM-CA	R	28.89 (2.41)	0.26	20.37 (5.09)	0.73	**<0.0001***
MICM-CA	L	28.15 (3.02)	0.26	20.11 (4.83)	0.73	**<0.0001***
SM-MPR	R	94.36 (5.46)	**0.04***	88.10 (6.43)	0.52	**0.009***
SM-MPR	L	93.20 (5.47)	**0.04***	87.79 (6.93)	0.52	**0.02***
FM-FM	-	44.67 (3.32)	-	42.38 (2.69)	-	0.05

Source: Research.

FM-SM: Distance from the mental foramen to the mandibular symphysis; FM-MPR: Distance from the mental foramen to the posterior margin of the mandibular ramus; FM-MICM: Distance from the mental foramen to the inferior border of

REMUNOM
ISSN 2178-6925

Received: 19/10/2026 - **Accepted:** 20/11/2026
Vol: 13.24
DOI: 10.66104/acsqf297
Pages: 1-19

the mandibular body; FM-MA: Distance from the mental foramen to the alveolar margin; MICM–CA: Distance from the inferior border of the mandibular body to the alveolar crest; SM-MPR: Distance from the mandibular symphysis to the posterior margin of the ramus; FM-FM: Mental foramen to mental foramen; R: Right side; L: Left side.
p: Level of statistical significance. (1): Based on paired t-test. (2): Based on independent t-test. (*): Significant difference at 5.0%.

REMUNOM
ISSN 2178-6925
Received: 19/10/2026 - **Accepted:** 20/11/2026
Vol: 13.24
DOI: 10.66104/acsqf297
Pages: 1-19

Graph 1. Representation of the measurements performed for the variables FM-SM, FM-MICM, FM-MA, and MICM-CA.

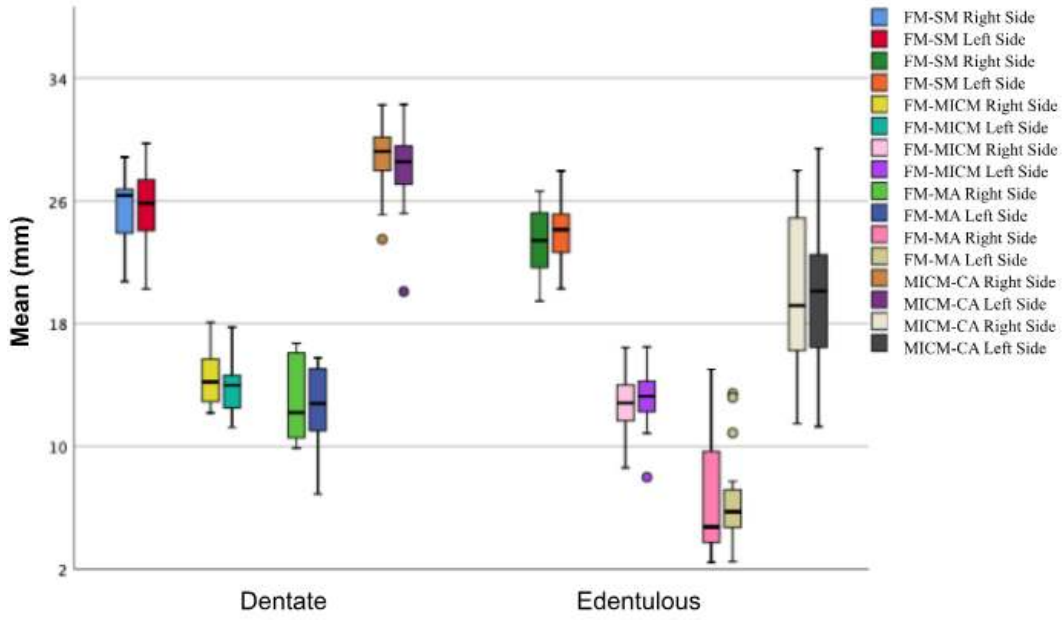

Graph 2. Representation of the measurements performed for the variables SM-MPR, FM-MPR, and FM-FM.

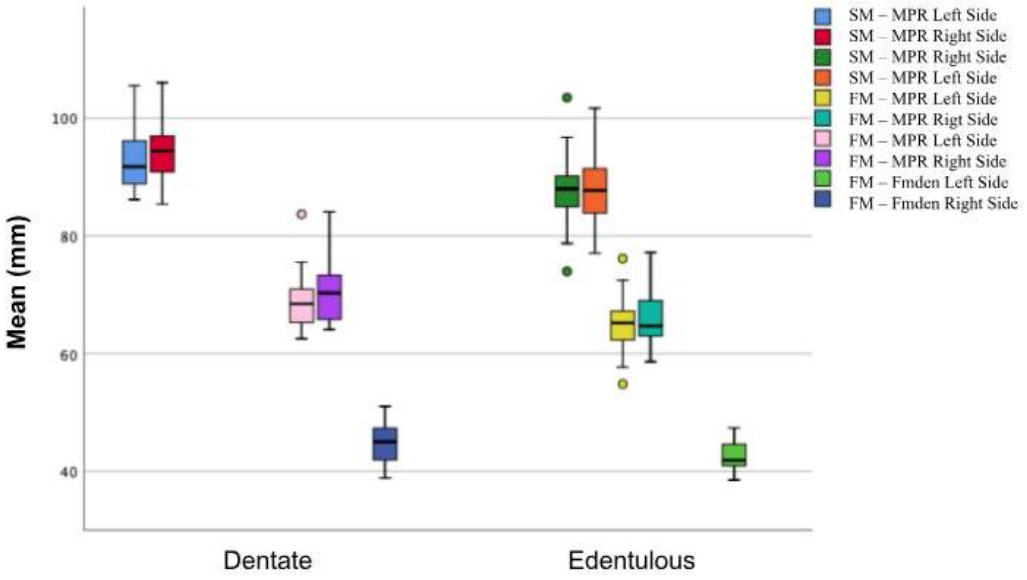

In intragroup measurements, comparing the variables on the right and left sides of the dentate mandible group, statistically significant differences were observed for the variables FM-MPR (p = 0.004) and SM-MPR (p = 0.04).

CC BY

REMUNOM
ISSN 2178-6925
Received: 19/10/2026 - **Accepted:** 20/11/2026
Vol: 13.24
DOI: 10.66104/acsqf297
Pages: 1-19

In the edentulous mandible group, no statistically significant differences were found between the horizontal and vertical distances on the right and left sides of the mandibles.

In the intergroup comparison (dentate vs. edentulous mandibles), statistically significant differences were observed in most variables, with higher measurements recorded in the dentate group. A significant difference between groups was found for the variable FM-SM on the right side ($p = 0.02$), but not on the left side ($p = 0.08$).

For the variable FM-MPR, a statistically significant difference was observed between the two groups on both the right side ($p = 0.01$) and the left side ($p = 0.03$).

Regarding FM-MICM, a statistically significant difference was found between groups on the right side ($p = 0.03$), but not on the left side ($p = 0.21$).

A statistically significant difference was also observed for SM-MPR in the intergroup comparison, on both the right side ($p = 0.009$) and the left side ($p = 0.02$).

For the variables FM-MA and MICM-CA, measurements were consistently smaller in edentulous mandibles compared to dentate mandibles on both sides, showing a statistically significant difference ($p < 0.0001$).

4. Discussion

The mental foramen (MF) allows the passage of the mental nerve, a branch of the inferior alveolar nerve, which provides sensory innervation to the lower lip, buccal vestibule, and gingiva mesial to the first mandibular molar (Charoenvicha *et al.*; Sancar and Dedeoğlu).

Accurate determination of the location and orientation of the MF is of paramount importance for both diagnostic and clinical procedures. Clinically, the mental nerve can be damaged during surgical interventions, leading to paresthesia or anesthesia. Knowledge of its precise location is also essential for the correct administration of local anesthetics and to avoid misdiagnoses of pathological conditions (Urîtu *et al.*; Kim and Hur).

The present study identified the most frequent location of the MF as being below the second mandibular premolar. These findings are consistent with previous reports (Alazemi *et al.*; Dall'Azen *et al.*). The second most frequent location was between the

CC BY

REMUNOM
ISSN 2178-6925
Received: 19/10/2026 - **Accepted:** 20/11/2026
Vol: 13.24
DOI: 10.66104/acsqf297
Pages: 1-19

mandibular premolars, as also reported in studies by Cartes *et al.* and Yanık and Nalbantoğlu. This information is clinically relevant to prevent injury to the neurovascular bundle during surgical procedures in the premolar and molar regions, and to ensure effective local anesthesia.

Studies conducted in different populations using dry mandibles most commonly report the mental foramen (MF) aligned with the apex of the mandibular second premolar (Bello *et al.*), although other authors have described its position between the premolars (Puri *et al.*), highlighting relevant anatomical variability.

In the present study, sex-based analyses were not performed due to the small number of female specimens, which limits comparative inferences. This methodological approach is consistent with previous investigations that did not identify significant differences between sexes regarding MF position (Ghandourah *et al.*).

In dentate mandibles, the distance from the mandibular symphysis to the MF (MF-SM) showed mean values of 25.57 mm (SD: 2.36) on the right side and 25.60 mm (SD: 2.45) on the left. These values are lower than those reported by Lima, who found measurements close to 29 mm, and also slightly lower than the mean of 27.47 mm (Hassan *et al.*).

Regarding the distance between the MF and the posterior border of the mandibular ramus (MF-BPR), values of 70.71 mm (SD: 5.47) on the right and 69.41 mm (SD: 5.57) on the left were observed, which are higher than those reported by Lima *et al.*, who found 67.73 mm and 64.94 mm, respectively. The distance between the MF and the inferior border of the mandibular body (MF-BICM) was 14.39 mm (SD: 1.86) on the right and 13.96 mm (SD: 1.81) on the left in dentate specimens. Additionally, it was observed that this measurement corresponds approximately to half of the distance between the inferior border and the alveolar crest, suggesting that the MF tends to occupy a relatively stable position at the mid-height of the mandibular body (Matveeva *et al.*; Gherghiţă *et al.*).

In edentulous mandibles, all linear measurements were consistently reduced compared to dentate specimens, with statistically significant differences ($p < 0.0001$) observed for the variables MF-AC and IMB-AC on both sides. The MF-AC distance

CC BY

REMUNOM
ISSN 2178-6925
Received: 19/10/2026 - **Accepted:** 20/11/2026
Vol: 13.24
DOI: 10.66104/acsqf297
Pages: 1-19

was 6.97 mm (SD: 4.12) on the right and 6.67 mm (SD: 3.35) on the left, values consistent with those reported by Piloto (Singh *et al.*), who described a wide range (2.02–9.82 mm on the right; 4.53–13.01 mm on the left). The IMB-AC distance showed mean values of 20.37 mm (SD: 5.09) on the right and 20.11 mm (SD: 4.83) on the left, slightly lower than those reported by Lima *et al.*. These findings reinforce that alveolar bone resorption associated with edentulism leads to significant dimensional changes in the mandible, directly affecting the relative position of the MF. Factors such as aging, tooth loss, and the degree of alveolar bone resorption play a determinant role in this anatomical variation (Nalbantoğlu *et al.*).

Regarding MF orientation, dentate mandibles showed a predominance of a descending oblique direction (92.85% on the right and 85.71% on the left). In edentulous mandibles, this pattern remained predominant on the left side (60%), whereas on the right side, a horizontal orientation was more frequent (53.33%), followed by the descending oblique orientation (40%). These findings indicate that, in most cases, the MF presents an opening trajectory directed from superior to inferior and from posterior to anterior, which is clinically relevant, particularly for the safe and effective administration of mental nerve blocks.

5. Conclusion

All mandibles analyzed presented mental foramina on both the right and left sides. The most frequent location was below the second mandibular premolar, with the most prevalent orientation being oblique descending, indicating an opening directed from superior to inferior and posterior to anterior.

The presence or absence of teeth significantly influences the position of the MF, as edentulism leads to alveolar bone resorption, reducing mandibular dimensions and altering the foramen's location.

Accurate knowledge of the position and morphology of the MF is essential for dental surgeons performing procedures in the mental region, minimizing the risk of accidents and complications during surgical or anesthetic interventions.

CC BY

REMUNOM
ISSN 2178-6925

Received: 19/10/2026 - **Accepted:** 20/11/2026
Vol: 13.24
DOI: 10.66104/acsqf297
Pages: 1-19

Financing

There was no funding for this research.

Conflicts of interest

All authors declare no conflicts of interest.

References

Alazemi, A., *et al.* "Evaluation of mental foramen and mandibular canal course and location in an Emirati subpopulation." *Int Dent J*, vol. 74, no. 5, 2024, pp. 1142-1150, https://doi.org/10.1016/j.identj.2024.03.014.

Amaan, M., *et al.* "Use of adult dry human mandibles to study of mandibular foramen from various bony landmarks." *J Pharm Bioallied Sci*, vol. 16, no. Suppl 1, 2024, pp. S666-S668, https://doi.org/10.4103/jpbs.jpbs_927_23.

Arthanari, A., *et al.* "Quantifying sexual dimorphism by analyzing ramus flexure and bigonial width in orthopantomography." *Cureus*, vol. 16, no. 6, 2024, article e61848, https://doi.org/10.7759/cureus.61848.

Bello, S. A., *et al.* "Mental foramen size, position and symmetry in a multi-ethnic, urban black population: radiographic evidence." *J Oral Maxillofac Res*, vol. 9, no. 4, 2018, article e2, https://doi.org/10.5037/jomr.2018.9402.

Bosykh, Y. Y., *et al.* "Cone beam computed tomography study on the relation between mental foramen and roots of mandibular teeth, presence of anterior loop and satellite foramina." *Morphologie*, vol. 103, no. 341 Pt 2, 2019, pp. 65-71, https://doi.org/10.1016/j.morpho.2019.04.002.

Bruna-Mejias, A., *et al.* "Morphological characteristics of the double mental foramen and its relevance in clinical practice: an observational study." *Diagnostics (Basel)*, vol. 14, no. 12, 2024, article 1277, https://doi.org/10.3390/diagnostics14121277.

Cartes, G., *et al.* "Mandibular canal course and the position of the mental foramen by panoramic X-ray in Chilean individuals." *Biomed Res Int*, vol. 2018, 2018, article 2709401, https://doi.org/10.1155/2018/2709401.

Charoenvicha, C., *et al.* "Positioning of the inferior alveolar nerve and surgical implications: a study on Thai mandibles." *Ann Plast Surg*, vol. 94, no. 5, 2025, pp. 589-594, https://doi.org/10.1097/SAP.0000000000004185.

Dall'Azen, G. C., *et al.* "Measurement of the mandibular canal and mandibular incisive canal using cone beam tomography in adults from South Brazil." *J Oral Sci*, vol. 66, no. 3, 2024, pp. 169-175, https://doi.org/10.2334/josnusd.24-0018.

De Silva, D. T., and U. C. P. Perera. "Morphometric analysis of mental foramen in retained cadaveric specimens of mandibles of Sri Lankan population." *Anat Sci Int*, 2025, https://doi.org/10.1007/s12565-025-00883-w.

CC BY

REMUNOM
ISSN 2178-6925

Received: 19/10/2026 - **Accepted:** 20/11/2026
Vol: 13.24
DOI: 10.66104/acsqf297
Pages: 1-19

Ghandourah, A. O., *et al.* "A radiographic analysis of the location of the mental foramen." *Saudi Dent J*, vol. 35, no. 4, 2023, pp. 354-358, https://doi.org/10.1016/j.sdentj.2023.03.001.

Gherghiţă, O. R., *et al.* "Direct and imaging morphometry for the localization of the mandibular foramen in dentate and edentulous human subjects." *Rom J Morphol Embryol*, vol. 61, no. 3, 2020, pp. 783-791, https://doi.org/10.47162/RJME.61.3.16.

Goyushov, S., *et al.* "Accessory mental/buccal foramina: case report and review of literature." *Implant Dent*, vol. 26, no. 5, 2017, pp. 796-801, https://doi.org/10.1097/ID.0000000000000646.

Habash, G., *et al.* "Anatomical variant of anteriorly extending mental foramen: a case report." *Clin Case Rep*, vol. 12, no. 1, 2024, article e8341, https://doi.org/10.1002/ccr3.8341.

Hassan, T. A. L., *et al.* "Morphometric analysis of the mental foramen variation in an Iraqi population by using cone-beam computed tomography." *J Craniofac Surg*, vol. 33, no. 3, 2022, pp. e247-e250, https://doi.org/10.1097/SCS.0000000000008029.

Kim, Y. H., and M. S. Hur. "Anatomical and CBCT-based evaluation of the mental foramen in Korean adults: clinical implications for implant surgery and mental nerve block." *Diagnostics (Basel)*, vol. 15, no. 24, 2025, article 3109, https://doi.org/10.3390/diagnostics15243109.

Lima, D. S. C., *et al.* "Caracterização anatômica do forame mentual em uma amostra de mandíbulas humanas secas brasileiras." *Rev Bras Cir Craniomaxilofac*, vol. 13, no. 4, 2010, pp. 230-235.

Liu, J., *et al.* "Comparison of endoscopic endonasal approach and lateral microsurgical infratemporal fossa approach to the jugular foramen: an anatomical study." *J Neurol Surg B Skull Base*, vol. 83, no. Suppl 2, 2021, pp. e474-e483, https://doi.org/10.1055/s-0041-1731034.

Mallahi, E., *et al.* "Anatomical characteristics of mental foramen and canal: a cone-beam computed tomography analysis." *J Clin Exp Dent*, vol. 16, no. 8, 2024, pp. e1004-e1011, https://doi.org/10.4317/jced.61861.

Matveeva, N., *et al.* "Morphological alterations in the position of the mandibular foramen in dentate and edentulous mandibles." *Anat Sci Int*, vol. 93, no. 3, 2018, pp. 340-350, https://doi.org/10.1007/s12565-017-0423-9.

Mohebiniya, M., and M. Kamani. "Multiple mental foramina: a rare anatomical variation detected by cone-beam computed tomography." *Cureus*, vol. 16, no. 6, 2024, article e63524, https://doi.org/10.7759/cureus.63524.

Nalbantoğlu, A. M., *et al.* "The location of mandibular foramen relative to the occlusal plane: a study on Anatolian dry mandible." *Eur Oral Res*, vol. 58, no. 1, 2024, pp. 51-57, https://doi.org/10.26650/eor.20241261599.

Puri, A., *et al.* "CBCT evaluation of the vital mandibular interforaminal anatomical structures." *Ann Maxillofac Surg*, vol. 10, no. 1, 2020, pp. 149-157, https://doi.org/10.4103/ams.ams_144_19.

Sancar, B., and N. Dedeoğlu. "Morphometric analysis of cleft lip palate and prognathic mandibles in relation to mandibular canal course." *J Craniofac Surg*, vol. 32, no. 2, 2021, pp. 694-697, https://doi.org/10.1097/SCS.0000000000007502.

CC BY

REMUNOM
ISSN 2178-6925

Received: 19/10/2026 - **Accepted:** 20/11/2026
Vol: 13.24
DOI: 10.66104/acsqf297
Pages: 1-19

Singh, Y., *et al.* "A morphometric study of the mandibular foramen, lingula, and the incidence of accessory mandibular foramina in dry mandibles." *Cureus*, vol. 17, no. 3, 2025, article e81087, https://doi.org/10.7759/cureus.81087.

Tiwari, N. "Left accessory mental foramen in dry mandibles in department of anatomy in a medical college: a descriptive cross-sectional study." *JNMA J Nepal Med Assoc*, vol. 60, no. 253, 2022, pp. 805-807, https://doi.org/10.31729/jnma.7770.

Urîtu, A., *et al.* "Imaging retrospective study regarding the variability of the osseous landmarks for IAN block." *J Clin Med*, vol. 14, no. 2, 2025, article 636, https://doi.org/10.3390/jcm14020636.

Yanık, D., and A. M. Nalbantoğlu. "Mental foramen and apical foramen: a dangerous anatomical proximity." *Aust Endod J*, vol. 50, no. 2, 2024, pp. 352-358, https://doi.org/10.1111/aej.12852.

Zmyslowska-Polakowska, E., *et al.* "Evaluation of size and location of a mental foramen in the Polish population using cone-beam computed tomography." *Biomed Res Int*, vol. 2019, 2019, article 1659476, https://doi.org/10.1155/2019/1659476.

CC BY