REMUNOM
ISSN 2178-6925

Received: 15/10/2026 - **Accepted:** 11/11/2026
Vol: 13.24
DOI: 10.66104/0rpahk67
Pages: 1-13

CÔNDILO MANDIBULAR BÍFIDO: RELATO DE CASO DE UMA VARIAÇÃO ANATÔMICA BILATERAL

BIFID MANDIBULAR CONDYLE: CASE REPORT OF A BILATERAL ANATOMICAL VARIATION

CÓNDILO MANDIBULAR BÍFIDO: REPORTE DE CASO DE UNA VARIACIÓN ANATÓMICA BILATERAL

Antônio Veloso Correia Neto[1]; Bárbara Rachelli Farias Teixeira[2]; Arthur Felipe de Brito Andrade[3]; Ilan Hudson Gomes de Santana[4]*; Ana Karine Farias da Trindade[5]; Eliane Marques Duarte de Sousa[5]; Luciana Barbosa Sousa de Lucena[5]; Monique Danyelle Emiliano Batista Paiva[5]

[1] Graduate in Dentistry from the Federal University of Paraíba, Brazil.

[2] Doctoral Student in the Postgraduate Program in Dentistry at the Federal University of Paraíba, Paraíba, Brazil.

[3] Graduate Program in Oral Biology, School of Dentistry, University of Campinas, Piracicaba, São Paulo, Brazil.

[4] Undergraduate in Dentistry at the Federal University of Paraíba, Brazil.

[5] Professor in the Department of Morphology at the Federal University of Paraíba, Brazil.

* Corresponding author: Ilan Hudson Gomes de Santana. E-mail: ilan.hudson@academico.ufpb.br

Resumo

Objetivo: Relatar um caso raro de côndilo mandibular bífido (CMB) bilateral e descrever as alterações morfológicas associadas na fossa mandibular do osso temporal. Materiais e Métodos: Trata-se de um relato de caso observacional descritivo baseado em um crânio humano seco pertencente a uma coleção anatômica acadêmica. Foram realizadas avaliação macroscópica da mandíbula e da base do crânio, mensurações lineares das cabeças condilares com paquímetro digital e análise das relações anatômicas. Resultados: Observou-se bifurcação bilateral dos côndilos mandibulares, com cada côndilo dividido em duas cabeças articulares mediolaterais distintas, separadas por um sulco anteroposterior. As superfícies superiores apresentaram-se achatadas e irregulares, com dimensões mediolaterais máximas de 33 mm à direita e 30 mm à esquerda. As fossas mandibulares exibiram expansão lateral e subdivisão em áreas articulares distintas. Também foram identificadas alterações no processo zigomático do osso temporal, sugerindo remodelação adaptativa para acomodar as cabeças condilares duplicadas. Conclusão: O côndilo mandibular bífido constitui uma variação anatômica rara, frequentemente assintomática e detectada de forma incidental. A remodelação associada da fossa mandibular observada neste caso sugere possível mecanismo adaptativo para manutenção da função articular. O reconhecimento dessa variação é importante para o diagnóstico por imagem e para a tomada de decisão clínica em alterações da articulação temporomandibular.

Palavras-chave: Côndilo mandibular; Articulação temporomandibular; Remodelação óssea; Modelo anatômico.

Abstract

Objective: To report a rare case of bilateral bifid mandibular condyle (BMC) and describe the associated morphological alterations in the mandibular fossa of the temporal bone. Materials and Methods: This is a descriptive observational case report based on a dry human skull from an academic anatomical collection. Macroscopic evaluation of the mandible and skull base was performed to identify morphological variations. Linear measurements of the condylar heads were obtained using a digital

CC BY

REMUNOM
ISSN 2178-6925

Received: 15/10/2026 - **Accepted:** 11/11/2026
Vol: 13.24
DOI: 10.66104/0rpahk67
Pages: 1-13

caliper, and anatomical relationships were analyzed. The specimen was examined following standardized anatomical observation protocols. Results: Bilateral bifurcation of the mandibular condyles was observed, with each condyle divided into two distinct mediolateral articular heads separated by an anteroposterior groove. The condylar heads exhibited flattened and irregular superior surfaces, with mediolateral dimensions of 33 mm on the right and 30 mm on the left. Additionally, the mandibular fossae showed lateral expansion and subdivision into distinct articular areas. Alterations in the zygomatic process of the temporal bone were also identified, suggesting adaptive remodeling to accommodate the duplicated condylar heads. Conclusion: Bifid mandibular condyle is a rare anatomical variation, often asymptomatic and incidentally detected. The associated remodeling of the mandibular fossa observed in this case suggests a possible adaptive mechanism to maintain joint function. Knowledge of such variations is essential for accurate diagnosis, avoiding misinterpretation in imaging, and improving clinical decision-making in temporomandibular joint disorders.

Keywords: Mandibular condyle; Temporomandibular joint; Bone remodeling; Anatomic model.

Resumen

Objetivo: Presentar un caso raro de cóndilo mandibular bífido (CMB) bilateral y describir las alteraciones morfológicas asociadas en la fosa mandibular del hueso temporal. Materiales y Métodos: Se trata de un reporte de caso observacional descriptivo basado en un cráneo humano seco perteneciente a una colección anatómica académica. Se realizó una evaluación macroscópica de la mandíbula y de la base del cráneo, mediciones lineales de las cabezas condilares con calibrador digital y análisis de las relaciones anatómicas. Resultados: Se observó bifurcación bilateral de los cóndilos mandibulares, con cada cóndilo dividido en dos cabezas articulares mediolaterales distintas, separadas por un surco anteroposterior. Las superficies superiores eran aplanadas e irregulares, con dimensiones mediolaterales máximas de 33 mm a la derecha y 30 mm a la izquierda. Las fosas mandibulares mostraron expansión lateral y subdivisión en áreas articulares distintas. También se identificaron alteraciones en el proceso cigomático del hueso temporal, lo que sugiere una remodelación adaptativa para acomodar las cabezas condilares duplicadas. Conclusión: El cóndilo mandibular bífido es una variación anatómica rara, con frecuencia asintomática y detectada de manera incidental. La remodelación asociada de la fosa mandibular observada en este caso sugiere un posible mecanismo adaptativo para mantener la función articular. El reconocimiento de esta variación es importante para el diagnóstico por imagen y la toma de decisiones clínicas en los trastornos de la articulación temporomandibular.

Palabras clave: Cóndilo mandibular; Articulación temporomandibular; Remodelación ósea; Modelo anatómico.

1. Introduction

The temporomandibular joint (TMJ) is one of the most complex and functionally demanding joints of the human body due to its unique and simultaneous movements, making it the only freely movable joint in the skull (Manafikhi *et al.*). It is responsible for enabling smooth mandibular movements during mastication, swallowing, and speech, while also stabilizing its position and preventing dislocation caused by external or unusual forces (Raut *et al.*).

Embryologically, the TMJ develops within the mandibular arch and exhibits significant variations in size and weight during human development (Raeburn *et al.*). It is composed of bony and soft tissue components, with its articular surface covered by fibrocartilage. The bony structures that form the TMJ include the articular surfaces

CC BY

REMUNOM
ISSN 2178-6925

Received: 15/10/2026 - **Accepted:** 11/11/2026
Vol: 13.24
DOI: 10.66104/0rpahk67
Pages: 1-13

of the mandible and temporal bones. On the mandible, the mandibular head stands out as an ellipsoid anatomical structure located at the posterosuperior portion of the ramus. On the inferior surface of the squamous part of the temporal bone, from anterior to posterior, are the articular tubercle and the mandibular fossa, which is divided by the tympanosquamous fissure into a posterior portion corresponding to the tympanic part of the temporal bone and an anterior portion corresponding to the articular area of the mandibular fossa. The soft tissue components include the articular cartilage, articular disc, synovial membrane, articular capsule, and intrinsic and extrinsic ligaments (Polat *et al.*; Zhang *et al.*; Teixeira *et al.*).

As part of the TMJ structure, the mandibular head functions as the pivot point for mandibular rotation within the skull (Seok). The morphology of the mandibular head varies across age groups and among individuals. However, anatomically, it is typically described as a rounded bony structure with an oval and biconvex superior surface in the axial plane. Several studies analyzing large collections of dry skulls have classified mandibular heads into four morphological types: angular, convex, flattened, and rounded (Machado *et al.*).

Morphological and functional alterations of the mandibular head may occur due to variability in development and bone remodeling, which adapts to changes in growth patterns. Such variations can be associated with factors such as age, sex, ethnicity, occlusal forces, facial type, functional load, trauma, malocclusion, and other abnormalities related to developmental disorders, often occurring asymmetrically between the right and left sides (Machado *et al.*). Among these variations, the bifid mandibular condyle (BMC) has been described in the literature as a structural alteration of unknown etiology and uncertain biopathology, which in most cases is asymptomatic. Its discovery is usually incidental, often during routine imaging exams, and a detailed evaluation of these structures is essential for accurate diagnosis and to guide appropriate clinical or surgical management (Limongi *et al.*).

From a clinical perspective, several etiological theories have been proposed for BMC, including trauma to the condylar cartilage during growth, embryological septation persistence, and genetic predisposition. Although most cases are asymptomatic, imaging-based investigations have suggested potential associations

CC BY

REMUNOM
ISSN 2178-6925

Received: 15/10/2026 - **Accepted:** 11/11/2026
Vol: 13.24
DOI: 10.66104/0rpahk67
Pages: 1-13

with joint noise, deviation during mouth opening, and intermittent locking. Recent advances in CBCT and micro-CT have improved the diagnostic characterization of this variation (Xiao and Ni).

Therefore, a thorough understanding of TMJ anatomy is essential for differentiating normal anatomical conditions from variations, enabling more precise diagnostic assessments and supporting the choice of appropriate therapeutic approaches (Evenhuis *et al.*; Vilar *et al.*). In this context, the present study aims to report a bilateral bifid mandibular condyle as an anatomical variant and to describe the morphological alterations observed in the mandibular fossa of the temporal bone.

2. Case Report

This study was conducted in compliance with Brazilian legislation that authorizes the use of unclaimed cadavers for research and educational purposes, according to Law No. 8501 of November 30, 1992, and in accordance with Resolution No. 466/2012 of the National Health Council (CNS-MS).

The guidelines for this descriptive observational study involved the use of an anatomical specimen belonging to the teaching collection of the Department of Morphology (DMORF) at the Health Sciences Center (CCS) of the Federal University of Paraíba. This specimen is part of the didactic material used for theoretical and practical demonstrations during the Dental Anatomy course. During routine observation of the specimen, an alteration in the morphology of the mandibular head and the mandibular fossa of the temporal bone was detected, which prompted the development and execution of the present study.

Upon examination, the mandible (Figures 1 and 2) revealed a bilateral bifurcation of the mandibular head, where each condyle is divided into two parts, forming two distinct mediolateral articular surfaces separated by an anteroposterior groove: one surface facing the medial aspect of the mandibular ramus and the other continuous with the superior margin of the ramus along the anteroposterior axis formed by the coronoid process and the mandibular notch. The superior surfaces of the condyles are flattened and rough, exhibiting irregular calcification. The maximum mediolateral dimensions of the condylar heads were measured at 33 mm on the right side and 30 mm on the left side, respectively.

CC BY

REMUNOM
ISSN 2178-6925

Received: 15/10/2026 - **Accepted:** 11/11/2026
Vol: 13.24
DOI: 10.66104/0rpahk67
Pages: 1-13

Figure 1. Superior view of the mandible showing bilateral bifid mandibular condyles (BMC). CL = lateral condylar head; CM = medial condylar head; arrow = anteroposterior groove.

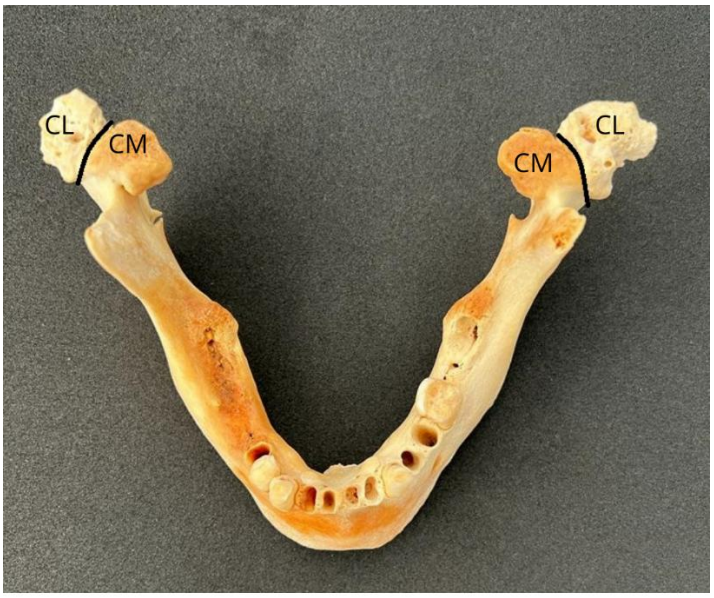

Source: DMORF/CCS/UFPB, Collection (001/2012)

Figure 2. Mandible in left superolateral view, highlighting the mediolateral arrangement of the heads (CM: medial head; CL: lateral head) and the groove (black arrow) that separates them.

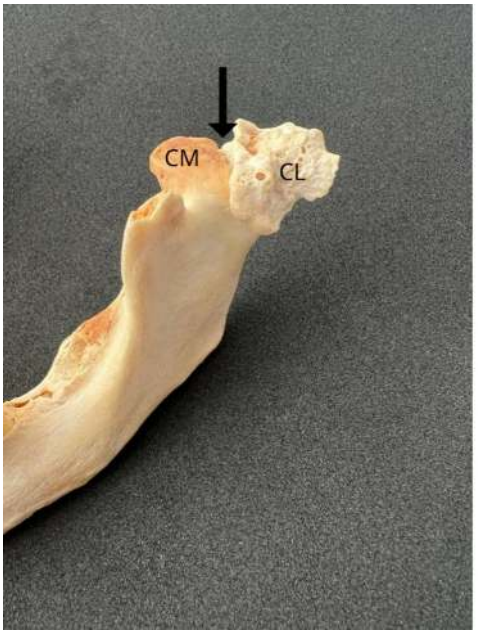

Source: DMORF/CCS/UFPB, Collection (002/2012)

REMUNOM
ISSN 2178-6925

Received: 15/10/2026 - **Accepted:** 11/11/2026
Vol: 13.24
DOI: 10.66104/0rpahk67
Pages: 1-13

When analyzing the skull base, it is observed that one of the superior articular bony surfaces, the mandibular fossa, is also subdivided into two portions: a smooth, medial portion and an irregular, lateral portion (Figures 3 and 4).

Figure 3: Inferior view of the left mandibular fossa of the left temporal bone, showing the increased size of this fossa. (FM: Medial fossa; FL: Lateral fossa)

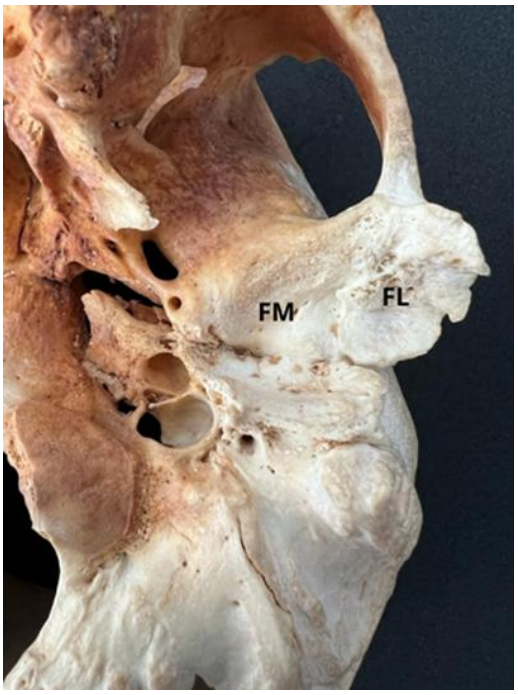

Source: DMORF/CCS/UFPB, Collection (003/2012)

REMUNOM
ISSN 2178-6925

Received: 15/10/2026 - **Accepted:** 11/11/2026
Vol: 13.24
DOI: 10.66104/0rpahk67
Pages: 1-13

Figure 4: View of the right side of the skull base, highlighting the double mandibular fossae. (FM: Medial fossa; FL: Lateral fossa)

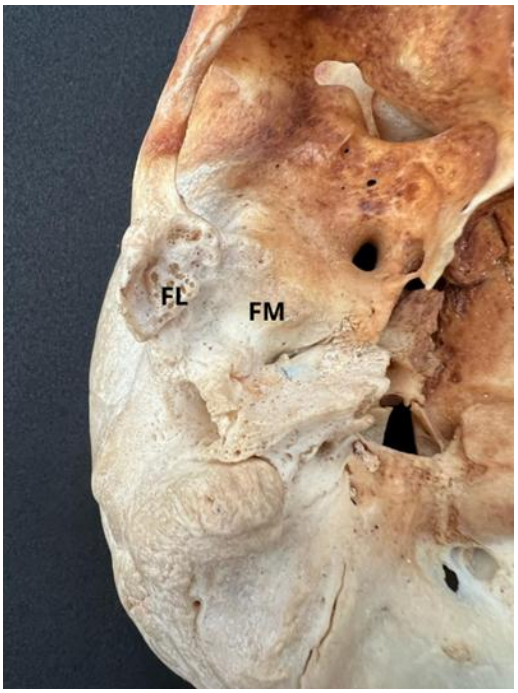

Source: DMORF/CCS/UFPB, Collection (004/2012)

In lateral and inferior views, the skull presents a morphological alteration in the zygomatic process of the temporal bone, where a downward projection emerges from its inferior margin, resembling a cardiac atrium. (Figures 5, 6A, and 6B).

REMUNOM
ISSN 2178-6925

Received: 15/10/2026 - **Accepted:** 11/11/2026
Vol: 13.24
DOI: 10.66104/0rpahk67
Pages: 1-13

Figure 5: Inferior view of the skull base showing the enlarged zygomatic tubercles.



Source: DMORF/CCS/UFPB Collection (002/2012)

Figure 6A: Right lateral view of the skull with alteration in the articular tubercle of the zygomatic process of the right temporal bone. Figure 6B: Left lateral view of the skull with alteration in the articular tubercle of the zygomatic process of the left temporal bone.



Source: DMORF/CCS/UFPB Collection (002/2012)

REMUNOM
ISSN 2178-6925

Received: 15/10/2026 - **Accepted:** 11/11/2026
Vol: 13.24
DOI: 10.66104/0rpahk67
Pages: 1-13

3. Methodology

3.1 Measurement protocol

Linear dimensions were obtained using a digital caliper (precision 0.01 mm). Three repeated measurements were performed for each condylar head, and mean values were calculated by a single calibrated examiner. The mandible was positioned in the Frankfurt horizontal plane to minimize measurement bias. Shrinkage associated with cadaveric desiccation was acknowledged as a limitation.

4. Discussion

The temporomandibular joint (TMJ) is generally regarded as the most complex joint in the human body, classified as a synovial joint and, consequently, a diarthrosis. Its superior osseous surfaces, located in the neurocranium, are represented by the articular tubercle and the mandibular fossa, which are part of the squamous portion of the temporal bone. The inferior articular surface belongs to the viscerocranium and is represented by the mandibular head. This joint undergoes significant changes throughout its developmental process, starting from fetal growth and continuing through the first months of life, during which malformations or trauma can lead to anatomical variations (Madeira; Moore *et al.*).

Considering the anatomical framework of the area of interest, the mandible, shaped like a horseshoe, is a gnathic bone housing the lower teeth. It can be divided into three regions: an anterior portion forming the body of the bone, and two posterior portions—known as the rami—located on each side. Each ramus presents two upward projections along its superior margin. From anterior to posterior, these projections are the coronoid process and the condylar process, where the mandibular head is located—the focus of this study (Teixeira *et al.*).

The mandibular head articulates with the articular portion of the mandibular fossa on the inferior surface of the squamous part of the temporal bone. The movements performed by this articulation enable essential functions such as mastication, swallowing, and speech (Teixeira *et al.*). However, developmental alterations of the TMJ may occur, including the bifid mandibular condyle (BMC), although it is not listed as a bony variation in the primary reference text on cranial morphological variations (Michalski *et al.*).

CC BY

REMUNOM
ISSN 2178-6925

Received: 15/10/2026 - **Accepted:** 11/11/2026
Vol: 13.24
DOI: 10.66104/0rpahk67
Pages: 1-13

BMC was first described in 1941 by Hrdlicka, who examined dry male and female human skulls from the Smithsonian Institution collection (Hrdlicka). Later, in 1948, Schier reported the first case in a living population. Neves *et al.* reported that this variation is extremely uncommon and remains a rare condition despite increasing reports (Neves *et al.*). Hrdlicka described BMCs as being divided by a fissure or groove of variable depth (Hrdlicka), while Dennison *et al.* emphasized that true BMC involves multiple condylar heads observable in different anatomical planes (Dennison *et al.*). Lopez-Lopez *et al.* proposed that true BMC should originate from the neck of the condylar process, regardless of spatial orientation (Lopez-Lopez *et al.*).

Other studies have reported that BMC morphology ranges from shallow grooves to two distinct mandibular heads, with divisions oriented mediolaterally or anteroposteriorly (Zengin *et al.*). However, a definitive consensus on BMC definition remains controversial (Guven). In the present anatomical finding, the mandibular head was divided by an anteroposterior groove, forming two heads, corroborating previous findings (Mahapatra *et al.*). Additionally, the mandibular fossa showed lateral expansion toward the zygomatic process, suggesting adaptive remodeling to accommodate the additional condylar head.

Regarding prevalence, Menezes *et al.* identified BMC in only 0.018% of more than 50,000 panoramic radiographs, with bilateral cases accounting for 22% (Menezes *et al.*). Miranda *et al.* also reported predominance of unilateral cases and no clear sex or racial predilection (Miranda *et al.*). The present bilateral case aligns with these less frequent findings. Although most BMC cases are asymptomatic, some reports describe joint sounds, pain, deviation, ankylosis, and intermittent locking, highlighting the need for careful differential diagnosis. Etiology remains unclear, with trauma, genetic factors, infections, radiation, and embryopathies proposed (Guven; Neves *et al.*).

The prevalence of BMC is likely underestimated (Miloglu *et al.*), as most cases are detected incidentally during imaging exams (Jordana *et al.*; Miloglu *et al.*). Advances in 3D imaging allow more accurate diagnostic assessment (Neves *et al.*), and careful correlation with clinical data is essential (Tanner *et al.*). Management should be symptom-based and follows TMJ dysfunction protocols, including

CC BY

REMUNOM
ISSN 2178-6925

Received: 15/10/2026 - **Accepted:** 11/11/2026
Vol: 13.24
DOI: 10.66104/0rpahk67
Pages: 1-13

pharmacological and conservative therapies (Romero-Reyes *et al.*). Surgical treatment is reserved for cases with ankylosis (Corchero-Martín *et al.*).

According to D'Angelo and Fattini, anatomical variations do not cause functional impairment (D'Angelo and Fattini), whereas anomalies result in dysfunction (Tortora and Derrickson). Machado *et al.* classified BMC as an anatomical variation due to its predominantly asymptomatic presentation (Machado *et al.*). Anatomical teaching using cadaveric specimens is essential for identifying such variations and improving clinical preparedness (Asante *et al.*; Thune *et al.*). This case is limited by the absence of clinical history and imaging follow-up.

5. Conclusion

The bifurcation of the mandibular head is classified as one of the main anatomical alterations affecting the superior bony structure of the mandibular condylar process. It is considered a rare condition, characterized by the presence of a fissure dividing the anatomical structure into two lobes.

Recognition of BMC improves radiological interpretation, prevents misdiagnosis, and enriches anatomical teaching in dentistry curricula.

Although this morphological alteration is related to the framework of the temporomandibular joint (TMJ), in most cases, it does not lead to functional impairments in individuals with this condition.

Regarding the etiology of this structural alteration, studies indicate that it remains uncertain; however, potential causal factors include developmental disorders, genetic predisposition, nutritional issues, trauma, and surgical interventions, among others.

The present study reports a case involving a dry human skull, in which a bilateral bifurcation of the mandibular heads was observed, representing a rare finding in the literature. Furthermore, it was noted that the mandibular fossa exhibited lateral widening, suggesting an adaptive modification of this structure to accommodate the dual mandibular heads, possibly minimizing functional disturbances for the individual.

This emphasizes the importance of knowledge of anatomical variations for the proper training of future healthcare professionals.

CC BY

REMUNOM
ISSN 2178-6925

Received: 15/10/2026 - **Accepted:** 11/11/2026
Vol: 13.24
DOI: 10.66104/0rpahk67
Pages: 1-13

Funding

There was no funding for this research.

Conflicts of interest

All authors declare no conflicts of interest.

Clinical trial number

Not applicable

References

Asante, E. A., *et al.* "Perception and attitude of medical students towards cadaveric dissection in anatomical science education." *Ethiop J Health Sci,* vol. 31, no. 4, 2021, pp. 867–74, https://doi.org/10.4314/ejhs.v31i4.22.

Corchero-Martín, G., *et al.* "Bifid condyle: case report." *Med Oral Patol Oral Cir Bucal,* vol. 10, no. 3, 2005, pp. 277–9.

Dennison, J., *et al.* "The false and the true bifid condyles." *Homo,* vol. 59, no. 2, 2008, pp. 149–59.

D'Angelo, J. G., and C. C. Fattini. *Anatomia sistêmica e segmentar.* 3ª ed., Atheneu, 2007.

Evenhuis, J., *et al.* "Systematic assessment of mammalian skull specimens for dental and temporomandibular joint pathology." *J Vis Exp,* no. 186, 2022, https://doi.org/10.3791/64223.

Guven, O. "A study on etiopathogenesis and clinical features of multi-headed (bifid and trifid) mandibular condyles and review of the literature." *J Craniomaxillofac Surg,* vol. 46, no. 5, 2018, pp. 773–8.

Hrdlicka, A. "Lower jaw: double condyles." *Am J Phys Anthropol,* vol. 28, 1941, pp. 75–89.

Jordana, X., *et al.* "Bifid mandibular condyle: archaeological case report of a rare anomaly." *Dentomaxillofac Radiol,* vol. 33, no. 4, 2004, pp. 278–81.

Limongi, M. C., *et al.* "Alterações na articulação temporomandibular: relato de dois casos clínicos – côndilo bífido e anquilose da articulação temporomandibular." *Rev CEFAC,* vol. 21, no. 2, 2019.

Lopez-Lopez, J., *et al.* "Bifid condyle: review of the literature of the last 10 years and report of two cases." *Cranio,* vol. 28, no. 2, 2010, pp. 136–40.

Machado, F. A., *et al.* "Bilateral fusion between neck and mandibular condyle: a case report with clinical and anatomical significance." *Acta Sci Anat,* vol. 1, no. 2, 2019, pp. 147–52.

Madeira, M. C. *Anatomia da face.* 7ª ed., Sarvier, 2010.

Mahapatra, S., *et al.* "Anatomical variants of condylar process, coronoid process, and sigmoid notch in a Maharashtrian population: a radiographic study." *Cureus,* vol. 15, no. 6, 2023, article e40434, https://doi.org/10.7759/cureus.40434.

Manafikhi, M., *et al.* "Evaluation of the efficacy of platelet rich fibrin (I-PRF) intra-articular injections in the management of internal derangements of temporomandibular joints – a controlled preliminary prospective clinical study." *BMC Musculoskelet Disord,* vol. 23, no. 1, 2022, article 454, https://doi.org/10.1186/s12891-022-05421-7.

Menezes, A. V., *et al.* "The prevalence of bifid mandibular condyle detected in a Brazilian population." *Dentomaxillofac Radiol,* vol. 37, no. 4, 2008, pp. 220–3.

Michalski, C. D., *et al.* "Bifid mandibular condyle with associated temporomandibular joint ankylosis: a rare skeletal abnormality." *Cureus,* vol. 14, no. 9, 2022, article e29624, https://doi.org/10.7759/cureus.29624.

Miloglu, O., *et al.* "The frequency of bifid mandibular condyle in a Turkish patient population." *Dentomaxillofac Radiol,* vol. 39, no. 1, 2010, pp. 42–6.

CC BY

REMUNOM
ISSN 2178-6925

Received: 15/10/2026 - **Accepted:** 11/11/2026
Vol: 13.24
DOI: 10.66104/0rpahk67
Pages: 1-13

Miranda, K., *et al.* “Treatment of atypical bifid mandibular condyle associated with ankylosis of the temporomandibular joint.” *Case Rep Surg,* vol. 2019, 2019, pp. 1–8.

Moore, K. L., *et al. Anatomia orientada para a clínica.* 7ª ed., Guanabara Koogan, 2014.

Neves, F. S., *et al.* “Detection of bifid mandibular condyle by panoramic radiography and cone beam computed tomography.” *Braz J Oral Sci,* vol. 12, no. 1, 2013, pp. 16–9.

Polat, S., *et al.* “Temporomandibular joint and masticatory muscles morphometry and morphology in healthy subjects and individuals with temporomandibular dysfunction: an anatomical, radiological, and machine learning application study.” *Medicine (Baltimore),* vol. 103, no. 50, 2024, article e40846, https://doi.org/10.1097/MD.0000000000040846.

Raeburn, K., *et al.* “The maxillary vein: an anatomical narrative review with clinical implications for oral and maxillofacial surgeons.” *Anat Cell Biol,* vol. 58, no. 3, 2025, pp. 317–21, https://doi.org/10.5115/acb.25.024.

Raut, M., *et al.* “Prosthetic rehabilitation of a hemi-mandibulectomy patient with interim mandibular guide flange and maxillary twin occlusion: a case report.” *J Pharm Bioallied Sci,* vol. 16, no. Suppl 3, 2024, pp. S3009–S3011, https://doi.org/10.4103/jpbs.jpbs_521_24.

Romero-Reyes, M., *et al.* “Pharmacological management of orofacial pain.” *Drugs,* vol. 83, no. 14, 2023, pp. 1269–92, https://doi.org/10.1007/s40265-023-01927-z.

Seok, H. “Mandibular condylar head regeneration owing to remodeling of the costochondral graft after condylectomy for odontogenic myxoma.” *J Craniofac Surg,* vol. 36, no. 4, 2025, pp. e369–e371, https://doi.org/10.1097/SCS.0000000000010824.

Tanner, J. M., *et al.* “Bilateral bifid mandibular condyles diagnosed with three-dimensional reconstruction.” *Dentomaxillofac Radiol,* vol. 41, no. 8, 2012, pp. 691–5.

Teixeira, L. M. S., *et al. Anatomia aplicada à odontologia.* 3ª ed., Guanabara Koogan, 2020.

Thune, N. H., *et al.* “Retention of skull anatomy knowledge in dental education: a comparative study.” *Front Dent Med,* vol. 6, 2025, article 1596610, https://doi.org/10.3389/fdmed.2025.1596610.

Tortora, G. J., and B. Derrickson. *Princípios de anatomia e fisiologia.* 14ª ed., Guanabara Koogan, 2016.

Vilar, E. G. S., *et al.* “Indicações cirúrgicas de deslocamento do disco articular da articulação temporomandibular.” *Braz J Health Rev,* vol. 3, no. 5, 2020, pp. 13790–809.

Xiao, M., and S. Ni. “Different effects of abnormal mechanical stress on temporomandibular joint cartilage, subchondral bone, and discs.” *Front Physiol,* vol. 16, 2025, article 1539342, https://doi.org/10.3389/fphys.2025.1539342.

Zengin, A. Z., *et al.* “Assessment of temporomandibular joint morphology of bifid mandibular condyles: a cone beam computed tomography study.” *Folia Morphol (Warsz),* vol. 84, no. 3, 2025, pp. 655–63, https://doi.org/10.5603/fm.104250.

Zhang, Y., *et al.* “Three-dimensional spatial analysis of temporomandibular joint in adolescent Class II division 1 malocclusion patients: comparison of Twin-Block and clear functional aligner.” *Head Face Med,* vol. 20, no. 1, 2024, article 4, https://doi.org/10.1186/s13005-023-00404-y.