REMUNOM
ISSN 2178-6925

Received: 03/09/2026 - **Accepted:** 05/10/2026
Vol: 13.21
DOI: 10.66104/3h81dv12
Pages: 1-14

AVALIAÇÃO DA OZONIOTERAPIA COMO MÉTODO ADJUVANTE NO TRATAMENTO DE INFECÇÕES ODONTOGÊNICAS

EVALUATION OF OZONE THERAPY AS AN ADJUVANT METHOD IN THE TREATMENT OF ODONTOGENIC INFECTIONS

EVALUACIÓN DE LA OZONOTERAPIA COMO MÉTODO ADYUVANTE EN EL TRATAMIENTO DE INFECCIONES ODONTOGÉNICAS

Denis Zangrando[1]*; Elio Hitoshi Shinohara[1]; Ilan Hudson Gomes de Santana[2]; Fernando Kendi Horikawa[1]; Eduardo Sant'Ana [3]

[1] Oral and Maxillofacial Surgeon at the Regional Hospital of Osasco, Osasco, São Paulo, Brazil
[2] Dentist graduated from the Federal University of Paraíba, João Pessoa, Paraíba, Brazil
[3] Professor in the area of Oral and Maxillofacial Surgery at the University of São Paulo, Bauru, São Paulo, Brazil
*Corresponding author: Denis Zangrando, University of São Paulo, São Paulo, Brazil. E-mail: denis.zangrando@gmail.com

Resumo

A ozonioterapia tem sido investigada como abordagem adjuvante em odontologia devido às suas propriedades antimicrobianas e potencial modulador da resposta inflamatória. Este ensaio clínico randomizado exploratório avaliou a água ozonizada como adjuvante ao tratamento padrão de infecções odontogênicas graves, comparando-a à solução salina a 0,9% (SS). Trinta e oito pacientes foram alocados em dois grupos (n=19/grupo). Todos receberam drenagem cirúrgica, controle do foco quando possível, antibioticoterapia intravenosa padronizada e irrigação com 500 mL de água ozonizada ou SS. A trajetória da proteína C-reativa (PCR) entre D0, D3 e D7 foi considerada o desfecho principal para fins de análise deste relato; contagem de leucócitos e tempo de internação foram desfechos secundários. Modelos longitudinais por equações de estimação generalizadas mostraram redução temporal dos marcadores inflamatórios em ambos os grupos, sem evidência de interação grupo×tempo para PCR (p=0,889) ou leucócitos (p=0,613). Assim, os dados não demonstraram benefício incremental estatisticamente detectável da água ozonizada sobre a SS quando adicionada ao tratamento padrão. O pequeno tamanho amostral, a ausência de cálculo amostral a priori e limitações na documentação de ocultação da alocação e cegamento restringem a precisão das estimativas. Estudos prospectivos adequadamente dimensionados e com desfechos clínicos pré-especificados são necessários.

Palavras-chave: Ozônio; Infecção focal dentária; Cirurgia bucal; Ensaio clínico.

Abstract

Ozone therapy has been investigated as an adjunctive approach in dentistry because of its antimicrobial properties and potential modulation of inflammatory responses. This exploratory randomized clinical trial evaluated ozonated water as an adjunct to standard treatment for severe odontogenic infections, compared with 0.9% normal saline (NS). Thirty-eight patients were allocated to two groups (n=19/group). All received surgical drainage, source control whenever feasible, standardized intravenous antibiotic therapy, and irrigation with 500 mL of ozonated water or NS. For analytical clarity in this report, the C-reactive protein (CRP) trajectory from D0 to D3 and D7 was treated as the primary outcome; leukocyte count and length of hospital stay were secondary outcomes. Longitudinal generalized estimating equation models showed improvement in inflammatory markers over time in both groups, without evidence of a group-by-time interaction for CRP (p=0.889) or leukocyte count (p=0.613). Therefore, these data did not demonstrate a statistically detectable incremental benefit of ozonated water over NS when added to standard care. The small sample, absence of an a priori sample-size calculation, and incomplete documentation of allocation

CC BY

REMUNOM
ISSN 2178-6925

Received: 03/09/2026 - **Accepted:** 05/10/2026
Vol: 13.21
DOI: 10.66104/3h81dv12
Pages: 1-14

concealment and blinding limit the precision and internal-validity assessment of the findings. Adequately powered prospective trials with pre-specified clinical outcomes are warranted.

Keywords: Ozone; Focal infection, dental; Surgery, oral; Clinical trial.

Resumen

La ozonoterapia se ha investigado como abordaje adyuvante en odontología por sus propiedades antimicrobianas y su posible modulación de la respuesta inflamatoria. Este ensayo clínico aleatorizado exploratorio evaluó el agua ozonizada como complemento del tratamiento estándar de infecciones odontogénicas graves, comparándola con solución salina al 0,9% (SS). Treinta y ocho pacientes fueron asignados a dos grupos (n=19/grupo). Todos recibieron drenaje quirúrgico, control del foco cuando fue posible, antibioticoterapia intravenosa estandarizada e irrigación con 500 mL de agua ozonizada o SS. Para fines analíticos de este informe, la trayectoria de la proteína C reactiva (PCR) entre D0, D3 y D7 se consideró el desenlace principal; el recuento leucocitario y la duración de la hospitalización fueron desenlaces secundarios. Los modelos longitudinales mediante ecuaciones de estimación generalizadas mostraron mejoría temporal de los marcadores inflamatorios en ambos grupos, sin evidencia de interacción grupo×tiempo para PCR (p=0,889) ni leucocitos (p=0,613). Por lo tanto, estos datos no demostraron un beneficio incremental estadísticamente detectable del agua ozonizada frente a la SS añadida al tratamiento estándar. El pequeño tamaño muestral, la ausencia de cálculo muestral a priori y la documentación incompleta sobre ocultación de la asignación y cegamiento limitan la precisión y la evaluación de la validez interna. Se requieren ensayos prospectivos adecuadamente dimensionados y con desenlaces clínicos preespecificados.

Palabras clave: Ozono; Infección focal dental; Cirugía oral; Ensayo clínico.

1. INTRODUCTION

Ozone therapy has been investigated as a non-pharmacological adjunct in several areas of medicine and dentistry. Ozone (O_3), delivered as a controlled oxygen–ozone mixture, has high oxidative reactivity and has demonstrated antimicrobial activity in experimental and clinical settings. Proposed biological effects include oxidation of microbial cellular components and modulation of local redox and inflammatory pathways. However, the magnitude and clinical relevance of these effects vary substantially according to concentration, formulation, exposure time, and disease context [1–3].

Odontogenic infections, in turn, constitute a frequent concern in dental practice due to their potential progression to severe and, in some cases, fatal complications. These infections, often originating from periodontal and pulpal pathologies, may spread through the fascial spaces of the face and neck, resulting in conditions such as cellulitis, abscesses, and Ludwig's angina. If untreated or inadequately managed, these conditions may lead to serious systemic complications, including mediastinitis, cavernous sinus thrombosis, necrotizing fasciitis, and even death. Conventional management of these infections involves surgical drainage, removal of the infectious focus when possible, antibiotic therapy, and multidisciplinary clinical support; however, outcomes may be limited in cases of antimicrobial resistance or compromised general health status of the patient [4,5].

In dentistry, ozone has been studied as an adjunct in periodontal therapy, medication-related osteonecrosis of the jaws, and postoperative care. Evidence across indications is heterogeneous, and many studies are small or use different ozone formulations, concentrations, comparators, and outcomes [6,7]. Acute severe odontogenic infections remain underrepresented in this literature, particularly with respect to whether ozonated-water irrigation provides additional benefit beyond surgical drainage, source control, antibiotics, and mechanical irrigation.

Accordingly, the present exploratory randomized trial examined whether irrigation with ozonated water, when added to the standard surgical and antibiotic protocol for severe odontogenic infections, was associated with a different inflammatory trajectory compared with irrigation using 0.9% normal saline. Because the original study documentation did not define a formal non-inferiority or equivalence framework, the trial is interpreted as a superiority-oriented exploratory comparison; failure to detect a difference is not interpreted as evidence of equivalence.

CC BY

REMUNOM
ISSN 2178-6925

Received: 03/09/2026 - **Accepted:** 05/10/2026
Vol: 13.21
DOI: 10.66104/3h81dv12
Pages: 1-14

2. MATERIALS AND METHODS

This study was approved by the Brazilian National Research Ethics Committee (Comissão Nacional de Ética em Pesquisa – CONEP), under CAAE No. 22092719.1.0000.5417, on November 7, 2019. All participants received verbal and written information regarding the objectives, risks, and potential benefits of the study and signed the informed consent form before enrollment. The available manuscript records did not separately document assent and guardian-consent procedures for participants aged 12–17 years; this reporting limitation is acknowledged. Ethics approval should not be interpreted as equivalent to prospective clinical-trial registration.

2.1 Study design

This was a controlled, randomized, prospective, parallel-arm exploratory clinical trial conducted to evaluate whether ozonated-water irrigation provided an incremental effect when added to the standard treatment of severe odontogenic infection, compared with 0.9% normal saline irrigation. The original protocol did not document a non-inferiority/equivalence margin and did not include an a priori sample-size calculation; therefore, the study is reported as an exploratory superiority-oriented trial.

2.2 Study population

Patients who sought care or were referred to the Regional Hospital of Osasco within the Brazilian Unified Health System (SUS/SP) were screened. For this study, a severe odontogenic infection was operationally defined as an odontogenic infection requiring hospital management and presenting facial edema and trismus, leukocytosis on complete blood count, and clinical signs of oral infection requiring surgical drainage/decompression.

Inclusion criteria were: individuals of both sexes and any race, aged >12 years, with an odontogenic infection fulfilling the operational severity criteria described above. Exclusion criteria were pregnancy, special cognitive needs that precluded standard study procedures, insufficient information in the medical record, or refusal to participate.

Sample size: no formal a priori sample-size or power calculation was documented. The analyzed sample comprised all 38 eligible participants enrolled during the recruitment period (19 per group). The limited sample size reduces precision and increases the possibility of failing to detect clinically relevant between-group differences.

2.3 Recruitment site and period

Patients were recruited between November 2019 and December 2021 at the Regional Hospital of Osasco (SUS-SP), a referral center for the treatment of severe odontogenic infections, ensuring specialized follow-up and standardization of the medical protocols used.

2.4 Study groups

Participants were allocated to the OZ or NS group using a computer-generated sequence created with Randomizer®. The available study records did not document the person who generated the sequence, the person who enrolled participants, the allocation ratio beyond the final 1:1 distribution, use of blocks or stratification, or a formal allocation-concealment mechanism (e.g., central randomization or sequentially numbered opaque envelopes). These aspects are therefore reported as methodological limitations rather than inferred retrospectively.

Group 1 (OZ): patients received conventional surgical treatment, including drainage and removal of the infectious focus whenever possible, associated with standardized antibiotic therapy and irrigation of the surgical sites with 500 mL of previously prepared ozonated water.

Group 2 (NS): patients underwent the same conventional surgical and antibiotic treatment protocol; however, irrigation of the surgical sites was performed using 500 mL of 0.9% normal saline solution.

2.5 Surgical procedure

Under intravenous general anesthesia, decompression and drainage of the involved fascial spaces were performed, with removal of the odontogenic focus whenever technically feasible. After exploration of the surgical sites, patients in the OZ group underwent irrigation with 500 mL of ozonated

CC BY

REMUNOM
ISSN 2178-6925

Received: 03/09/2026 - **Accepted:** 05/10/2026
Vol: 13.21
DOI: 10.66104/3h81dv12
Pages: 1-14

water (Figure 1B), followed by placement of No. 2 Penrose drains (Figure 1C). The NS group underwent the same surgical steps using 500 mL of 0.9% normal saline. All surgical procedures were performed by a single experienced operator (DZ). Because of the obvious procedural differences and operating-room workflow, blinding of the surgeon was not feasible. Whether participants, postoperative clinicians, laboratory personnel, or outcome assessors were blinded to group allocation was not documented in the available records.

Figure 1. Surgical procedure: irrigation of the surgical site with ozonated water and placement of a Penrose drain.

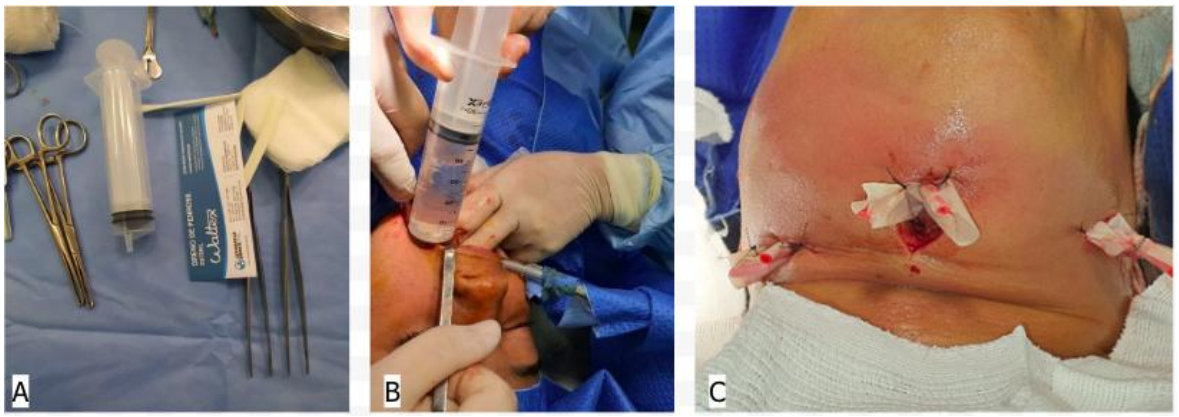

Source: Research images.

Figure 2. Representative contrast-enhanced CT images demonstrating a hypodense lesion with peripheral rim enhancement, a pattern strongly associated with a drainable abscess cavity.

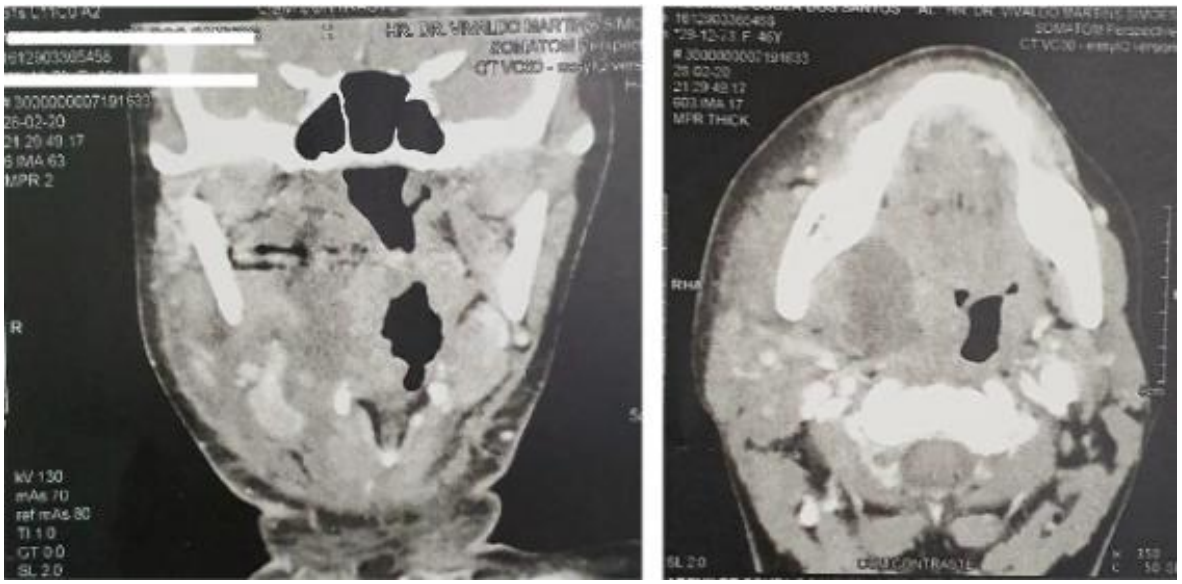

Source: Research images.

2.6 Preparation of ozonated water

Ozonated double-distilled water was prepared 30 minutes before surgery (Figure 3A) using an ozone generator (MedPlus model; Philozon®, Santa Catarina, Brazil) connected to a glass column with a catalytic converter and microbubble diffuser coupled to a stainless-steel tube (Figure 3B). Temperature was maintained at approximately 18 °C using a controlled refrigerator thermostat (Figure 3C). The generator was set to deliver ozone at 40 µg/mL for 30 minutes into 5,000 mL of bidistilled

CC BY

REMUNOM
ISSN 2178-6925

Received: 03/09/2026 - **Accepted:** 05/10/2026
Vol: 13.21
DOI: 10.66104/3h81dv12
Pages: 1-14

water (Fresenius Kabi Brasil LTDA, Aquiraz, CE, Brazil). Based on the approximately 20% transfer/absorption estimate described by Nogales et al. [9], the working concentration was estimated at approximately 8 µg/mL. The dissolved ozone concentration was not directly measured at the moment of clinical application; thus, 8 µg/mL should be interpreted as an estimated rather than analytically verified concentration. The 18 °C preparation temperature was used to reduce ozone decomposition during preparation and short-term handling; the exact interval from completion of preparation to irrigation was kept within the stated 30-minute preparation window.

Figure 3. Materials used for the preparation of the ozonated water solution.

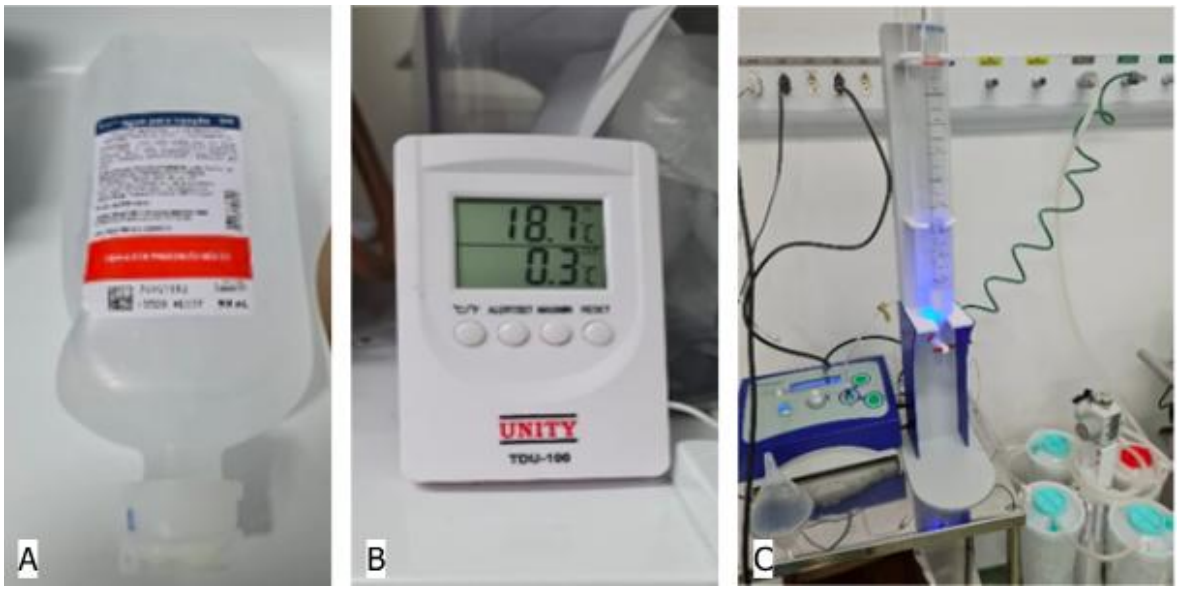

Source: Research images.

2.7 Postoperative care

All patients received hospital dietary support and dressing changes three times daily. Mouth rinses with 0.12% chlorhexidine were prescribed twice daily. Intravenous ceftriaxone plus clindamycin was administered according to the Hospital Infection Control Committee protocol; dose and duration were individualized according to hospital management and clinical evolution and were not available as a standardized participant-level dataset for this analysis. Previous outpatient antibiotic exposure was common but was not prospectively standardized or completely quantified, representing a potential confounder. Laboratory tests were processed by AFIP and collected at admission (D0) and after 3 (D3) and 7 (D7) days. Computed tomography was performed by FIDI when clinically indicated.

Outcome definition and statistical analysis: for reporting clarity, the longitudinal CRP trajectory (D0, D3, and D7) was designated as the primary analytical outcome in this report, although the original protocol did not document a single pre-specified primary endpoint; this post hoc reporting designation is a limitation. Leukocyte count and length of hospital stay were treated as secondary outcomes. Because CRP and leukocyte count were repeatedly measured within the same participants, longitudinal analyses were performed using generalized estimating equations (GEE) with an exchangeable working correlation structure and robust standard errors. CRP was log-transformed as log(CRP+0.1) because of marked right skew; leukocyte count was analyzed on its original scale. Fixed effects included group (OZ vs NS), time (D0, D3, D7), and the group×time interaction. The group×time interaction was the principal test of whether trajectories differed between treatment groups. Effect estimates are presented with 95% confidence intervals. Statistical significance was set at two-sided

CC BY

REMUNOM
ISSN 2178-6925

Received: 03/09/2026 - **Accepted:** 05/10/2026
Vol: 13.21
DOI: 10.66104/3h81dv12
Pages: 1-14

p<0.05. Length of stay was summarized descriptively because complete participant-level time-to-discharge data were not available for a robust inferential analysis.
Trial registration, masking, and safety reporting: no prospective clinical-trial registration number was documented in the study records available for this manuscript; this is acknowledged as a methodological limitation. No specific ozone-related adverse event was reported in the manuscript dataset; however, adverse events were not collected using a pre-specified structured safety instrument, so absence of reported events should not be interpreted as proof of absence.

3. RESULTS

A total of 38 participants were analyzed, with 19 in the OZ group and 19 in the NS group (Figure 4). No losses to follow-up were shown in the available CONSORT diagram. Sex distribution in the source figure was 8 men and 11 women in the NS group and 11 men and 8 women in the OZ group; this wording has been harmonized with Figure 5. Baseline CRP and leukocyte values were variable, but formal baseline comparisons did not show statistically significant group differences (CRP, Mann–Whitney p=0.530; leukocytes, Welch t test p=0.155). Available baseline characteristics are summarized in Table 1.

Table 1. Baseline characteristics available in the study dataset.

Characteristic	NS (n=19)	OZ (n=19)	Effect/test	p value
Sex, male/female, n	8/11	11/8	Descriptive	—
CRP at D0, mg/L, median (IQR)	13.0 (6.6–26.3)	16.4 (8.9–20.5)	Mann–Whitney U=158.5	0.530
Leukocytes at D0, ×10³/μL, mean ± SD	16.69 ± 6.61	14.10 ± 4.01	Welch t=1.46	0.155

IQR, interquartile range; CRP, C-reactive protein; NS, normal saline; OZ, ozonated water. Other potentially prognostic baseline variables, including anatomical extent, comorbidities, previous antibiotic exposure, ICU requirement, and immediate source removal, were not available as complete participant-level fields and were therefore not reconstructed or imputed.

CC BY

REMUNOM
ISSN 2178-6925

Received: 03/09/2026 - **Accepted:** 05/10/2026
Vol: 13.21
DOI: 10.66104/3h81dv12
Pages: 1-14

Figure 4. CONSORT flow diagram.

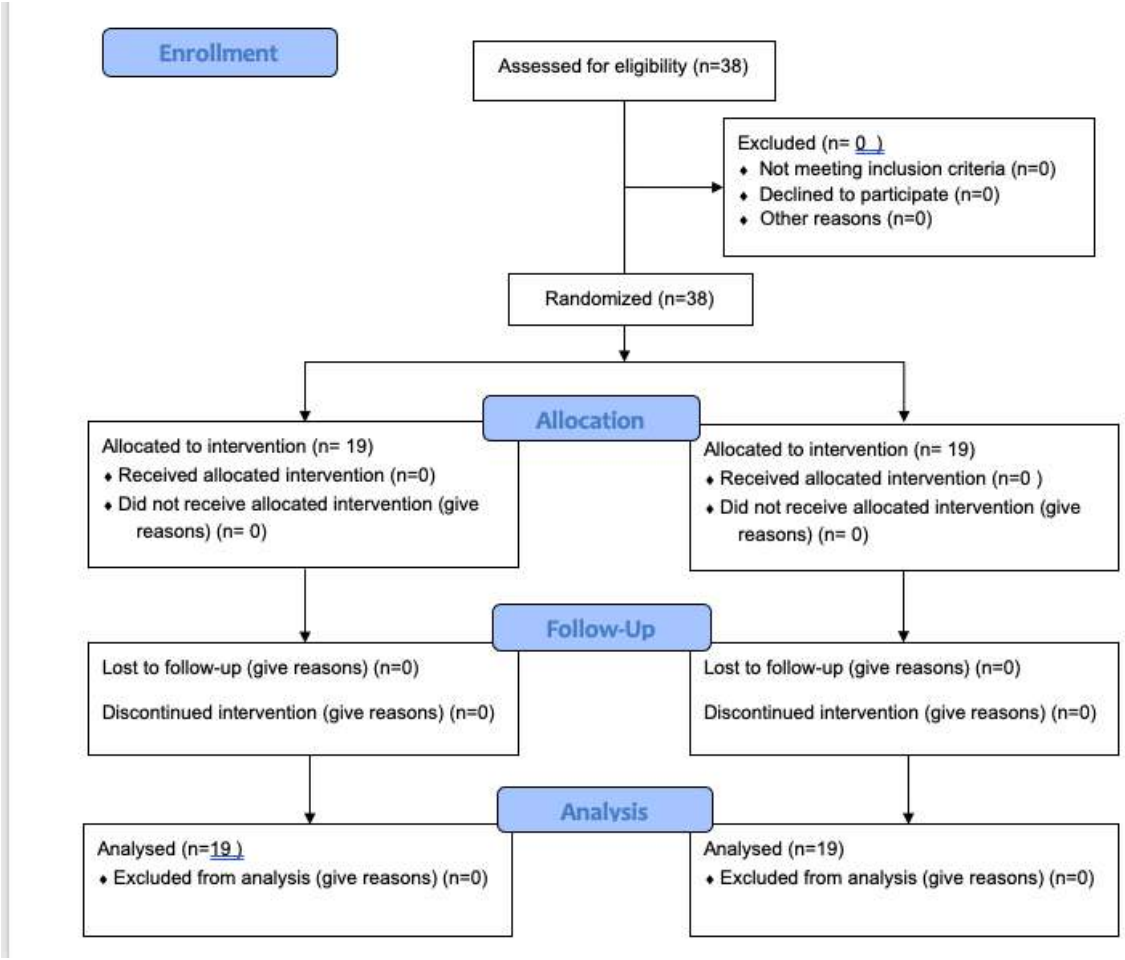

Source: Adapted from CONSORT.

Figure 5. Sex, age, and length of hospital stay among participants in the ozone and control groups.

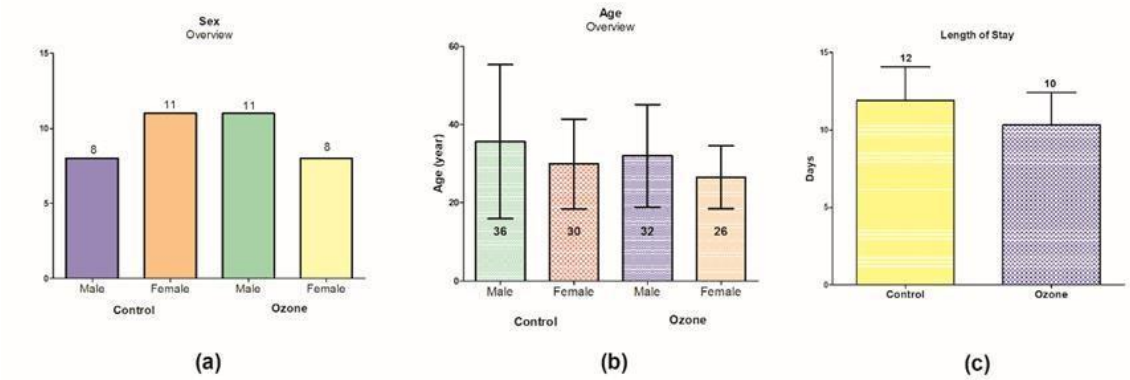

Source: Research data.

Hospital stay varied across participants, and some severe cases required prolonged admission and intensive-care support. General health status, anatomical extension, prior antimicrobial exposure, nutritional status, and the ability to achieve immediate source control are clinically important prognostic

CC BY

REMUNOM
ISSN 2178-6925

Received: 03/09/2026 - **Accepted:** 05/10/2026
Vol: 13.21
DOI: 10.66104/3h81dv12
Pages: 1-14

variables. However, these factors were not consistently available as structured participant-level variables in the analytical dataset and therefore could not be included in adjusted models.

Removal of the odontogenic focus was not always feasible at the initial procedure because of severe trismus or clinical complexity. Because the proportion of immediate source removal and the anatomical number of involved fascial spaces were not available as complete structured variables by treatment group, their potential confounding effects could not be quantified. This limitation should be considered when interpreting between-group estimates.

Figure 6. Leukocyte and C-reactive protein levels in the control and ozone groups according to follow-up day (D0, D3, and D7).

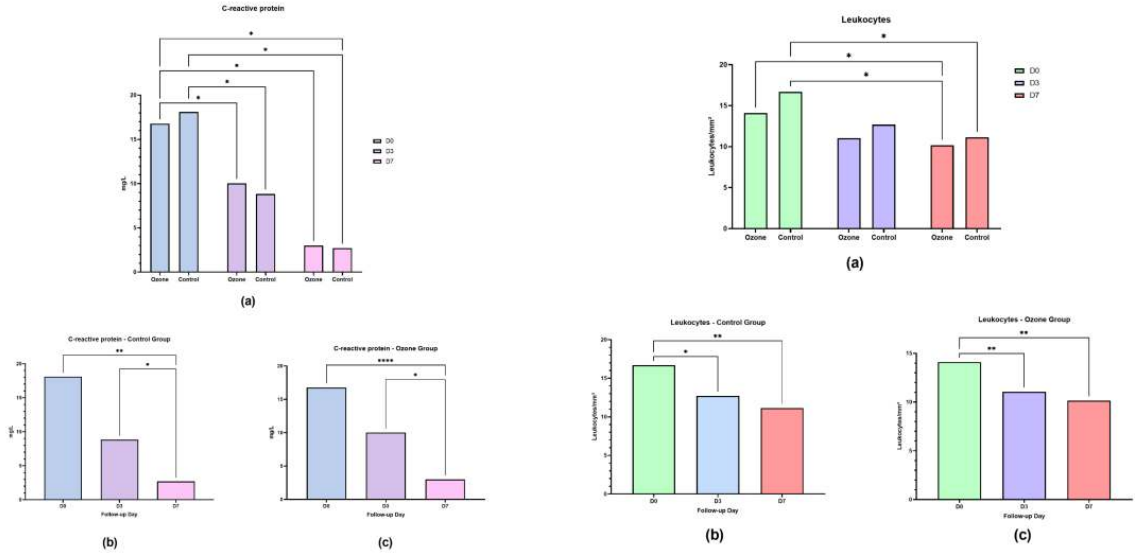

Source: Research data.

CRP decreased over time in both groups (Figure 7). Median CRP at D0 was 13.0 mg/L (IQR 6.6–26.3) in the NS group and 16.4 mg/L (IQR 8.9–20.5) in the OZ group. In the GEE model of log-transformed CRP, there was a strong time effect, but no evidence that the temporal trajectory differed between groups (global group×time Wald p=0.889). Relative to the NS group, the difference in change for OZ at D3 corresponded to a multiplicative interaction estimate of 1.14 (95% CI 0.59–2.22; p=0.695), and at D7 to 1.13 (95% CI 0.67–1.92; p=0.641). These estimates are compatible with both modest benefit and modest harm and do not support a claim of equivalence.

Observed CRP values were highly variable at D0 and D3, with several extreme values in both groups. By D7, values were low for most participants. The longitudinal model was therefore preferred over isolated time-point tests because it accounts for within-participant correlation and directly tests the group×time interaction.

Accordingly, the appropriate interpretation is that both groups showed substantial inflammatory improvement under standard hospital treatment, while this sample did not demonstrate a statistically detectable incremental CRP effect attributable to ozonated-water irrigation.

CC BY

REMUNOM
ISSN 2178-6925

Received: 03/09/2026 - **Accepted:** 05/10/2026
Vol: 13.21
DOI: 10.66104/3h81dv12
Pages: 1-14

Figure 7. Comparison of C-reactive protein (CRP) levels between the control group (normal saline—NS) and the ozone group (ozonated water—OZ) throughout follow-up.

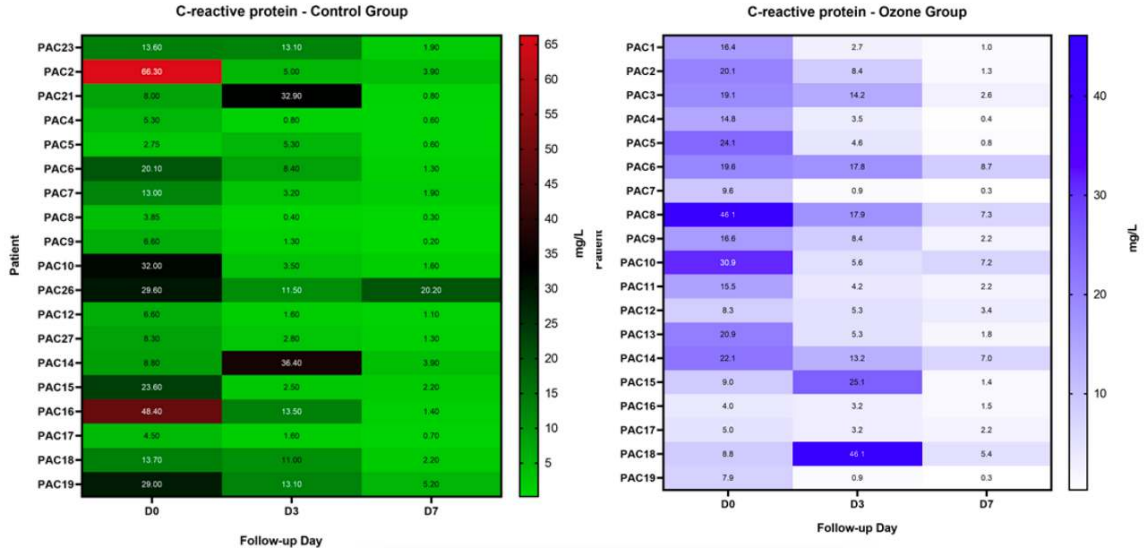

Source: Research data.

Leukocyte counts also decreased over time in both groups (Figure 8). At D0, mean leukocyte count was 16.69±6.61×10³/μL in the NS group and 14.10±4.01×10³/μL in the OZ group. The GEE model showed no significant group×time interaction (global Wald p=0.613). The OZ-versus-NS difference in change was +0.93×10³/μL at D3 (95% CI −2.23 to 4.09; p=0.564) and +1.60×10³/μL at D7 (95% CI −1.69 to 4.90; p=0.340).

Observed mean leukocyte counts were 12.71×10³/μL (NS) and 11.05×10³/μL (OZ) at D3 and 11.14×10³/μL (NS) and 10.16×10³/μL (OZ) at D7. Confidence intervals around the interaction estimates were wide, reflecting the small sample and limiting inference about clinically important differences.

Thus, leukocyte trajectories were consistent with clinical improvement in both groups, without evidence in this dataset that ozonated-water irrigation altered the rate of leukocyte decline relative to normal saline.

CC BY

REMUNOM
ISSN 2178-6925

Received: 03/09/2026 - **Accepted:** 05/10/2026
Vol: 13.21
DOI: 10.66104/3h81dv12
Pages: 1-14

Figure 8. Evolution of leukocyte levels in the control group (normal saline—NS) and ozone group (ozonated water—OZ) over the evaluated time periods.

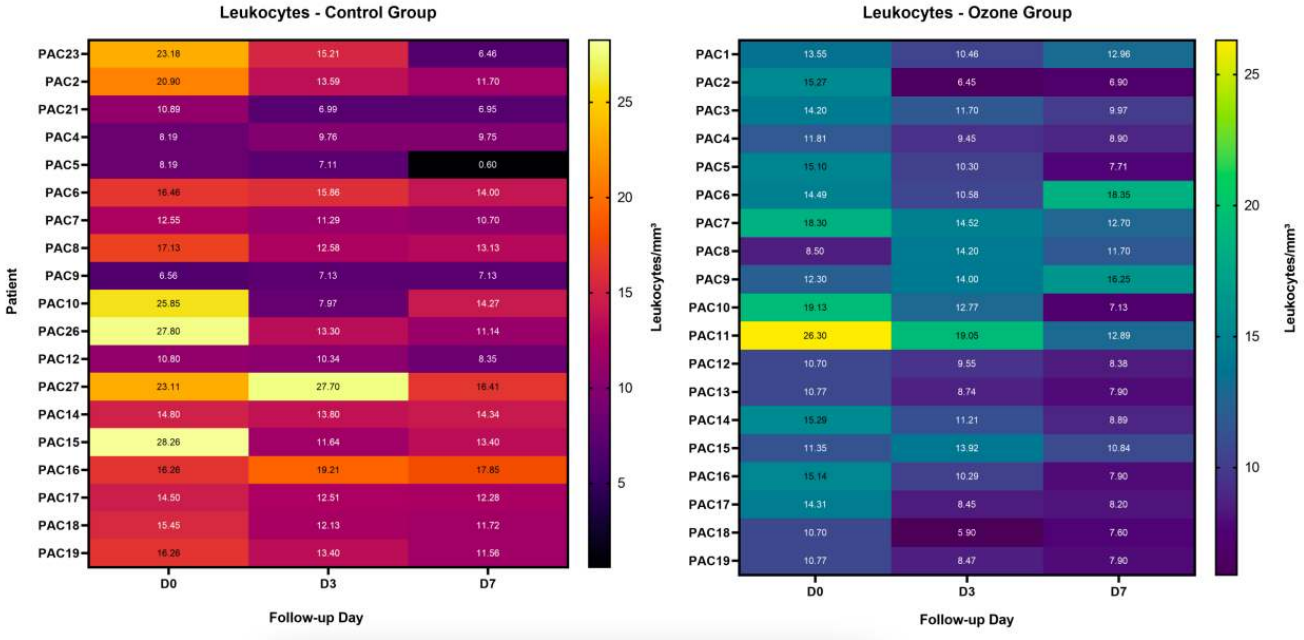

Source: Research data.

An immediate reduction in malodor was noted clinically in some patients after ozonated-water irrigation. Because odor was not measured using a validated scale, blinded assessors, repeated standardized time points, or a pre-specified analysis plan, this observation is considered exploratory and hypothesis-generating only and is not used as evidence of treatment efficacy.

Table 2. Longitudinal group×time interaction estimates from generalized estimating equation models.

Outcome	Interaction contrast	Estimate	95% CI	p value
CRP (log scale)	OZ×D3 vs NS×D3	0.133	−0.532 to 0.798	0.695
CRP (log scale)	OZ×D7 vs NS×D7	0.125	−0.401 to 0.651	0.641
Leukocytes, ×10³/μL	OZ×D3 vs NS×D3	+0.93	−2.23 to 4.09	0.564
Leukocytes, ×10³/μL	OZ×D7 vs NS×D7	+1.60	−1.69 to 4.90	0.340

Global group×time Wald tests: CRP p=0.889; leukocytes p=0.613. For CRP, exponentiating the interaction coefficients gives ratio-of-ratios estimates of 1.14 (D3) and 1.13 (D7).

4. DISCUSSION

The main finding of this exploratory randomized trial is that, within a standard treatment pathway dominated by surgical drainage, source control when feasible, intravenous antibiotics, and hospital support, inflammatory markers improved substantially over time in both groups. Longitudinal analyses did not detect a differential trajectory for CRP or leukocyte count between ozonated-water and normal-saline irrigation. Importantly, absence of statistical significance is not evidence of equivalence or non-inferiority, particularly in a sample of 19 participants per group with no a priori power calculation.

Previous clinical studies of ozone in oral care have primarily focused on periodontal therapy, endodontic protocols, postoperative morbidity, and osteonecrosis rather than acute deep-space odontogenic infection. Across these settings, results are heterogeneous and are difficult to compare because ozone formulation, concentration, exposure time, comparator irrigation, and outcome definitions vary considerably [9–18]. Periodontal irrigation studies are particularly relevant as mechanistic background because mechanical irrigation itself can reduce plaque, debris, and

CC BY

REMUNOM
ISSN 2178-6925

Received: 03/09/2026 - **Accepted:** 05/10/2026
Vol: 13.21
DOI: 10.66104/3h81dv12
Pages: 1-14

inflammatory mediators; however, these data should be regarded as indirect evidence rather than as proof of efficacy in severe odontogenic infection [10,11].

Different ozone formulations also have different pharmacological and biophysical characteristics. Ozonated oils may retain reactive products longer, gaseous ozone has high immediate reactivity, and ozonated water is convenient for irrigation but undergoes concentration decay. These differences reduce direct comparability between studies [12–14]. In the present study, the final 8 µg/mL concentration was estimated from generator output and an expected transfer fraction rather than directly measured at application, which adds exposure uncertainty.

Randomized studies of ozonated water or topical ozone after third-molar surgery have generally evaluated pain, edema, trismus, and patient comfort rather than severe infection control [16,17]. Some studies reported favorable within-group changes, whereas between-group differences were inconsistent. Such findings support biological plausibility and feasibility but cannot establish that ozone provides incremental benefit in hospitalized odontogenic infections.

The present findings are therefore best interpreted as a negative exploratory comparison rather than as demonstration that the two irrigants are equally effective. The confidence intervals around the interaction estimates remain compatible with clinically meaningful differences in either direction. Larger trials designed around an explicit primary endpoint are needed before claims of equivalence, non-inferiority, substitution, or antibiotic-sparing effects can be made.

Reports of ozone use in medication-related osteonecrosis and other chronic wound settings provide additional mechanistic context, but these conditions differ substantially from acute odontogenic infection in pathophysiology, microbial burden, tissue perfusion, and treatment goals [18]. They should therefore be cited as indirect background rather than as confirmatory evidence for the present indication.

A central interpretive issue is the strong therapeutic effect of the standard surgical protocol. Drainage, decompression, source control, intravenous antibiotics, repeated dressings, hydration, nutritional support, and inpatient monitoring are all expected to reduce inflammatory burden. Consequently, any incremental effect of the irrigating solution is likely to be smaller than the overall treatment effect and would require an adequately powered trial to detect. This is a treatment-context effect, not a placebo effect of surgery.

Normal saline is also an active mechanical irrigant rather than an inert pharmacological placebo. Lavage can remove debris, microorganisms, and soluble inflammatory products and can dilute local exudate. Accordingly, the control intervention should be described as standard mechanical irrigation with normal saline, and any between-group contrast represents the incremental effect of ozone beyond that mechanical effect [10,11].

Exposure characterization is another limitation. Although the estimated 8 µg/mL concentration was based on prior methodology [9], dissolved ozone was not directly quantified immediately before use, and ozone stability is influenced by temperature, water purity, time, and handling. Future trials should analytically verify concentration at the point of application and predefine exposure parameters, thereby improving reproducibility and dose–response interpretation.

The present data do not support claims that ozonated water can replace systemic antibiotics, reduce antibiotic duration, or serve as a proven alternative to established antiseptics. These clinically important hypotheses require dedicated outcomes such as total antimicrobial exposure, escalation or de-escalation of therapy, microbiological clearance, need for reintervention, ICU admission, readmission, and time to clinical resolution.

This study contributes clinical data in a scarcely studied indication, but several limitations constrain inference: small sample size without a priori power calculation; absence of a prospectively documented single primary endpoint; incomplete reporting of sequence implementation, allocation concealment, and blinding; lack of prospective trial registration in the available records; uncertainty in the analytically measured ozone concentration; incomplete structured baseline data on anatomical severity, previous antibiotics, comorbidities, ICU requirement, and immediate source control; and non-standardized assessment of odor. These limitations increase the risk of imprecision, residual confounding, and reporting bias and should be weighed alongside the randomized design.

CC BY

REMUNOM
ISSN 2178-6925

Received: 03/09/2026 - **Accepted:** 05/10/2026
Vol: 13.21
DOI: 10.66104/3h81dv12
Pages: 1-14

5. CONCLUSION

In this exploratory randomized trial, CRP and leukocyte counts decreased during standard treatment of severe odontogenic infections, but longitudinal analyses did not detect a statistically significant difference in trajectories between ozonated-water and normal-saline irrigation. The study therefore does not demonstrate superiority, equivalence, or non-inferiority of ozonated water. Given the small sample and methodological/reporting limitations, ozonated water should be regarded as an investigational adjunct in this setting. Future adequately powered, prospectively registered trials should use a pre-specified primary endpoint, verified ozone exposure, complete baseline severity characterization, and clinically relevant outcomes such as time to resolution, antibiotic exposure, reintervention, ICU admission, adverse events, and readmission.

STATEMENTS

Ethics

The study was approved by the Brazilian National Research Ethics Committee (Comissão Nacional de Ética em Pesquisa – CONEP), under CAAE No. 22092719.1.0000.5417, on November 7, 2019. Ethics approval is reported separately from clinical-trial registration.

Consent to participate

All adult participants signed the informed consent form before inclusion. The available manuscript records did not separately document assent/guardian-consent procedures for participants aged 12–17 years; this limitation is disclosed rather than reconstructed retrospectively.

Written consent for publication

Clinical images were de-identified in the manuscript. Specific written consent for publication of clinical photographs was not documented in the study records available to the authors; this should be considered when applying journal-specific publication-consent requirements.

Availability of data and materials

All data are available in the manuscript

Code availability

The longitudinal analyses were performed from participant-level values available in the study figures. No reusable statistical analysis code was archived with the original study dataset.

Trial registration

No prospective clinical-trial registration number was documented in the study records available for this manuscript. This is acknowledged as a limitation.

Funding

There was no funding for this research.

Authors' Contribution

CRediT author statement: Denis Zangrando (DZ): Conceptualization, Methodology, Investigation, Data curation, Writing – original draft, Writing – review & editing. Elio Hitoshi Shinohara (EHS): Methodology, Formal analysis, Interpretation, Writing – review & editing. Ilan Hudson Gomes de Santana (IHGS): Writing – review & editing, Visualization, Final approval. Fernando Kendi Horikawa (FKH): Writing – review & editing, Clinical interpretation, Final approval. Eduardo Sant'Ana (ESA): Conceptualization, Supervision, Project administration, Interpretation, Writing – review & editing. All authors approved the final manuscript and accept responsibility for their contributions.

CC BY

REMUNOM
ISSN 2178-6925

Received: 03/09/2026 - **Accepted:** 05/10/2026
Vol: 13.21
DOI: 10.66104/3h81dv12
Pages: 1-14

Conflicts of interest

All the authors declare no conflicts of interest.

REFERENCES

1. Bocci V. Biological and clinical effects of ozone has ozone therapy a future in medicine? Br J Biomed Sci.1999;56(4):270–9.
2. Elvis AM, Ekta JS. Ozone therapy: a clinical review. J Nat Sci Biol Med. 2011;2(1): 66–70.
3. Iorio, FBRD, Liberatore AMA, Koh IHJ, Otani C, Camilo FF. Ozonated mineral oil: preparation, characterization and evaluation of the microbicidal activity. Ozone Sci Eng. 2016;38(4):253-60
4. Topazian RG; Goldberg MH. Infecções maxilofaciais e orais. 3ª ed. São Paulo: Editora Santos; 1997.
5. Prabhu SR, Nirmalkumar ES. Acute fascial space infections of the neck: 1034 cases in 17 years follow up. Ann Maxillofac Surg. 2019;9(1):118-23.
6. Azarpazhooh H, Limeback The application of ozone in dentistry: a systematic review of literature. J Dent. 2008;36(2):104-16.
7. Ripmonti CI, Maniezzo M, Pessi MA, Boldini S. Treatment of osteonecrosis of the jaw (ONJ) by medical ozone gas insuflation: a case report. Tumori; 2012;98(3):72-5.
8. ESTRELA, Carlos. Metodologia científica: ciência, ensino, pesquisa. Artes médicas, 2018.
9. Nogales CG, Ferreira MB, Montemor AF, Rodrigues MF, Lage-Marques JL, Antoniazzi JH. Ozone therapy as an adjuvant for endodontic protocols: microbiological ex vivo study and cytotoxicity analyses. J Appl Oral Sci. 2016;24(6):607–613.
10. Habashneh R, Alsalman W, Khader Y. Ozone as an adjunct to conventional nonsurgical therapy in chronic periodontitis: a randomized controlled clinical trial. J Periodontal Res. 2015 Feb;50(1):37-43.
11. Chaves ES, Kornman KS, Manwell MA, Jones AA, Newbold DA, Wood RC. Mechanism of irrigation effects on gingivitis. J Periodontol. 1994;65(11):1016–1021.
12. Anzolin AP, da Silveira-Kaross NL, Bertol CD. Ozonated oil in wound healing: what has already been proven? Med Gas Res. 2020 Jan-Mar;10(1):54-59. doi: 10.4103/2045-9912.279985. PMID: 32189671; PMCID: PMC7871935.
13. Tualzik T, Chopra R, Gupta SJ, Sharma N, Khare M, Gulati L. Effects of ozonated olive oil and photobiomodulation using diode laser on gingival depigmented wound: A randomized clinical study. J Indian Soc Periodontol. 2021 Sep-Oct;25(5):422-426. doi: 10.4103/jisp.jisp_655_20. Epub 2021 Aug 30. PMID: 34667386; PMCID: PMC8452166.
14. Kuroda K, Azuma K, Mori T, Kawamoto K, Murahata Y, Tsuka T, Osaki T, Ito N, Imagawa T, Itoh F, Okamoto Y. The Safety and Anti-Tumor Effects of Ozonated Water in Vivo. Int J Mol Sci. 2015 Oct 22;16(10):25108-20. doi: 10.3390/ijms161025108. PMID: 26506343; PMCID: PMC4632793.
15. Cutler CW, Stanford TW, Abraham C, Cederberg RA, Boardman TJ, Ross C. Clinical benefits of oral irrigation for periodontitis are related to reduction of pro-inflammatory cytokine levels and plaque. J Clin Periodontol. 2000 Feb;27(2):134-43.
16. Rapone B, Ferrara E, Santacroce L, Topi S, Gnoni A, Dipalma G, Mancini A, Di Domenico M, Tartaglia GM, Scarano A, Inchingolo F. The Gaseous Ozone Therapy as a Promising Antiseptic Adjuvant of Periodontal Treatment: A Randomized Controlled Clinical Trial. Int J Environ Res Public Health. 2022 Jan 16;19(2):985.

CC BY

REMUNOM
ISSN 2178-6925

Received: 03/09/2026 - **Accepted:** 05/10/2026
Vol: 13.21
DOI: 10.66104/3h81dv12
Pages: 1-14

17. Glória JCR, Douglas-de-Oliveira DW, E Silva LDA, Falci SGM, Dos Santos CRR. Influence of ozonized water on pain, oedema, and trismus during impacted third molar surgery: a randomized, triple blind clinical trial. BMC Oral Health. 2020 Feb 5;20(1):41.
18. Sivalingam VP, Panneerselvam E, Raja KV, Gopi G. Does Topical Ozone Therapy Improve Patient Comfort After Surgical Removal of Impacted Mandibular Third Molar? A Randomized Controlled Trial. J Oral Maxillofac Surg. 2017 Jan;75(1):51.e1-51.e9.
19. Ludolph I, Fried FW, Kneppe K, Arkudas A, Schmitz M, Horch RE. Negative pressure wound treatment with computer-controlled irrigation/instillation decreases bacterial load in contaminated wounds and facilitates wound closure. Int Wound J. 2018 Dec;15(6):978-984. doi: 10.1111/iwj.12958. Epub 2018 Jul 4. PMID: 29974664; PMCID: PMC7949639.
20. Wang X, Tan J, Ni S, Zhou D, Liu B, Fu Q. Antimicrobial efficacy of composite irrigation solution against dominant pathogens in seawater immersion wound and in vivo wound healing assessment. Front Microbiol. 2023 May 25;14:1188373. doi: 10.3389/fmicb.2023.1188373. PMID: 37303778; PMCID: PMC10248133.]
21. Melanie P, Niola C, Plataroti I, Mancini S, Fratini F. Use of Ozone in Veterinary Dentistry as an Alternative to Conventional Antibiotics and Antiseptics. Vet Sci. 2024 Apr 3;11(4):163. doi: 10.3390/vetsci11040163. PMID: 38668430; PMCID: PMC11053877.
22. Williamson DA, Carter GP, Howden BP. Current and Emerging Topical Antibacterials and Antiseptics: Agents, Action, and Resistance Patterns. Clin Microbiol Rev. 2017 Jul;30(3):827-860. doi: 10.1128/CMR.00112-16. PMID: 28592405; PMCID: PMC5475228.
23. Gentili V, Strazzabosco G, Salgari N, Mancini A, Rizzo S, Beltrami S, Schiuma G, Casciano F, Alogna A, Passarella D, Davinelli S, Scapagnini G, Medoro A, Rizzo R. Ozonated Oil in Liposome Eyedrops Reduces the Formation of Biofilm, Selection of Antibiotic-Resistant Bacteria, and Adhesion of Bacteria to Human Corneal Cells. Int J Mol Sci. 2023 Sep 14;24(18):14078. doi: 10.3390/ijms241814078. PMID: 37762377; PMCID: PMC10531138.

CC BY